

El-Fiky's

MINI ATLAS OF
ANATOMY

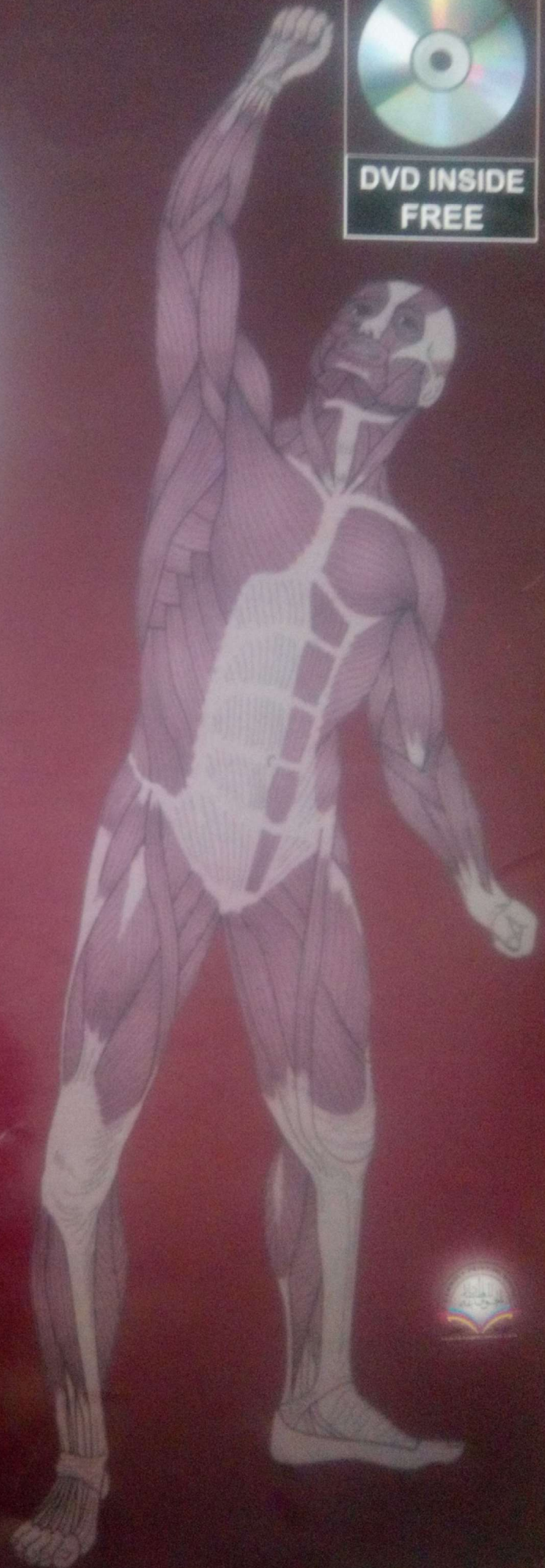


DR. MOHAMED EL-FIKY

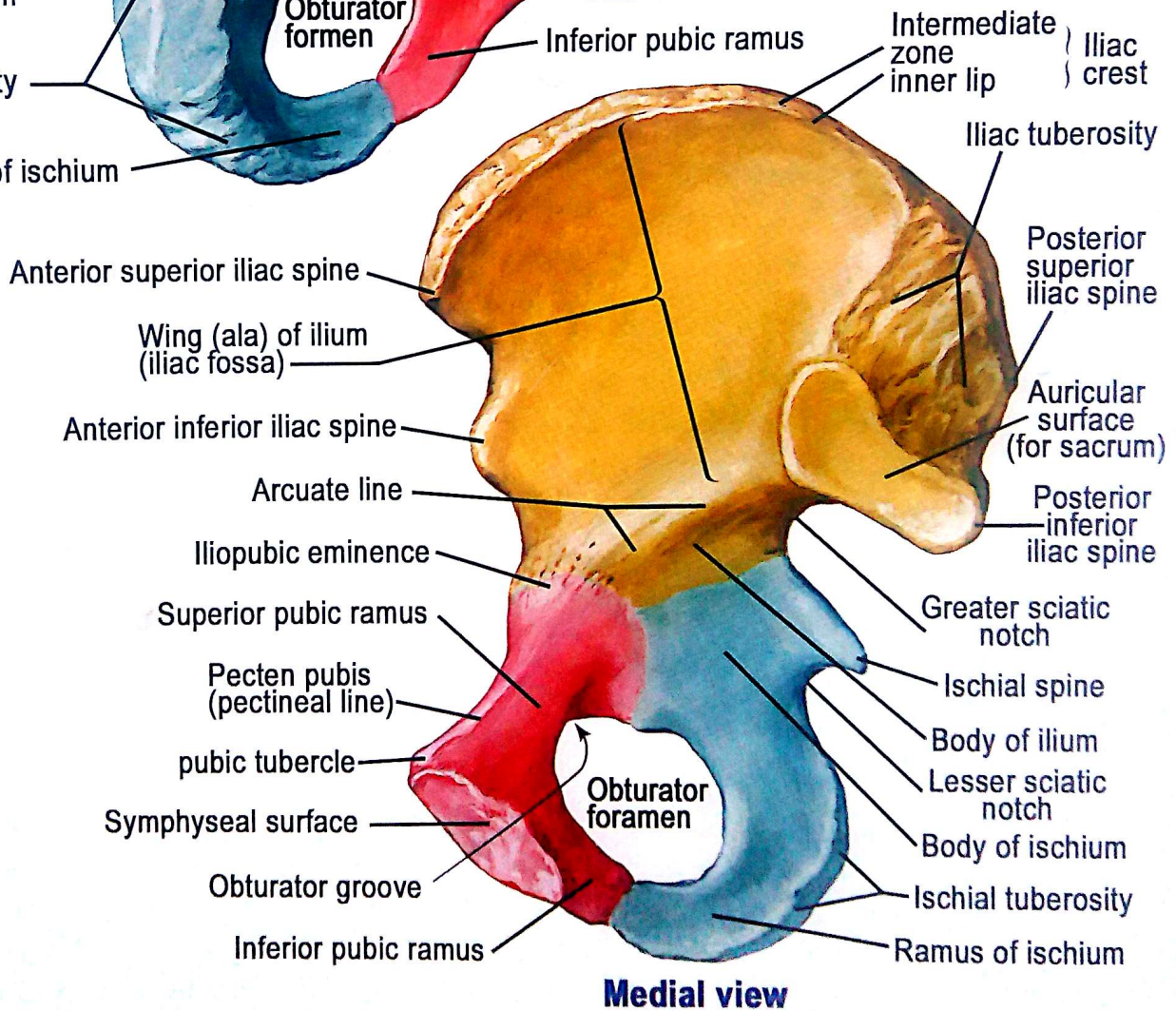
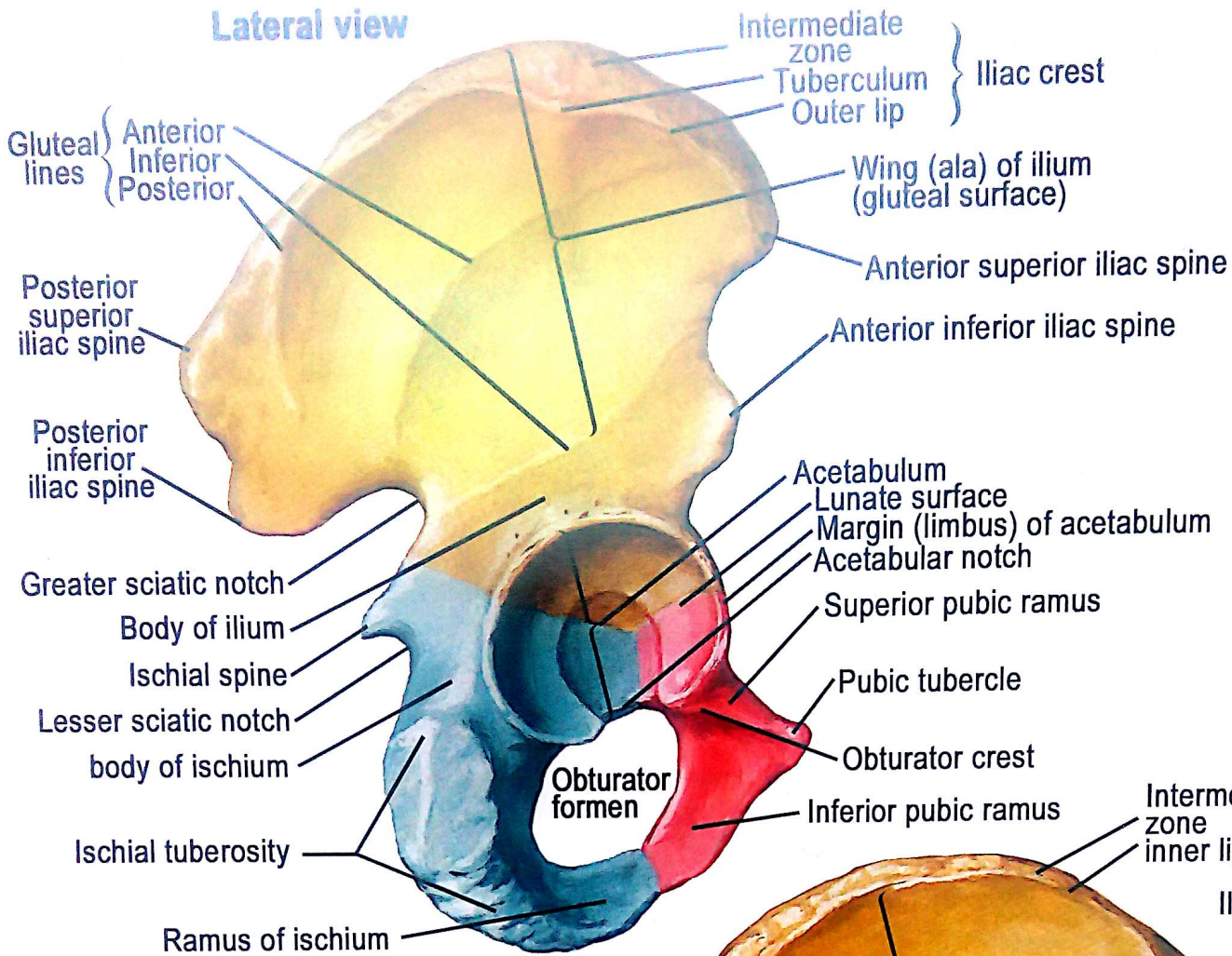
Ass. Prof. of Anatomy & embryology
Faculty of Medicine Menoufia University
E.mail: fiky@yahoo.com
Tel:(002) 0100 6662266

FIKY'S MINI ATLAS:

- 1- Part I thorax & vertebral column.
- 2- Part II abdomen , pelvis & perineium.
- 3- Part III upper limb.
- 4- Part IV lower limb.
- 5- Part V head and neck.
- 6- Part IV neuroanatomy.

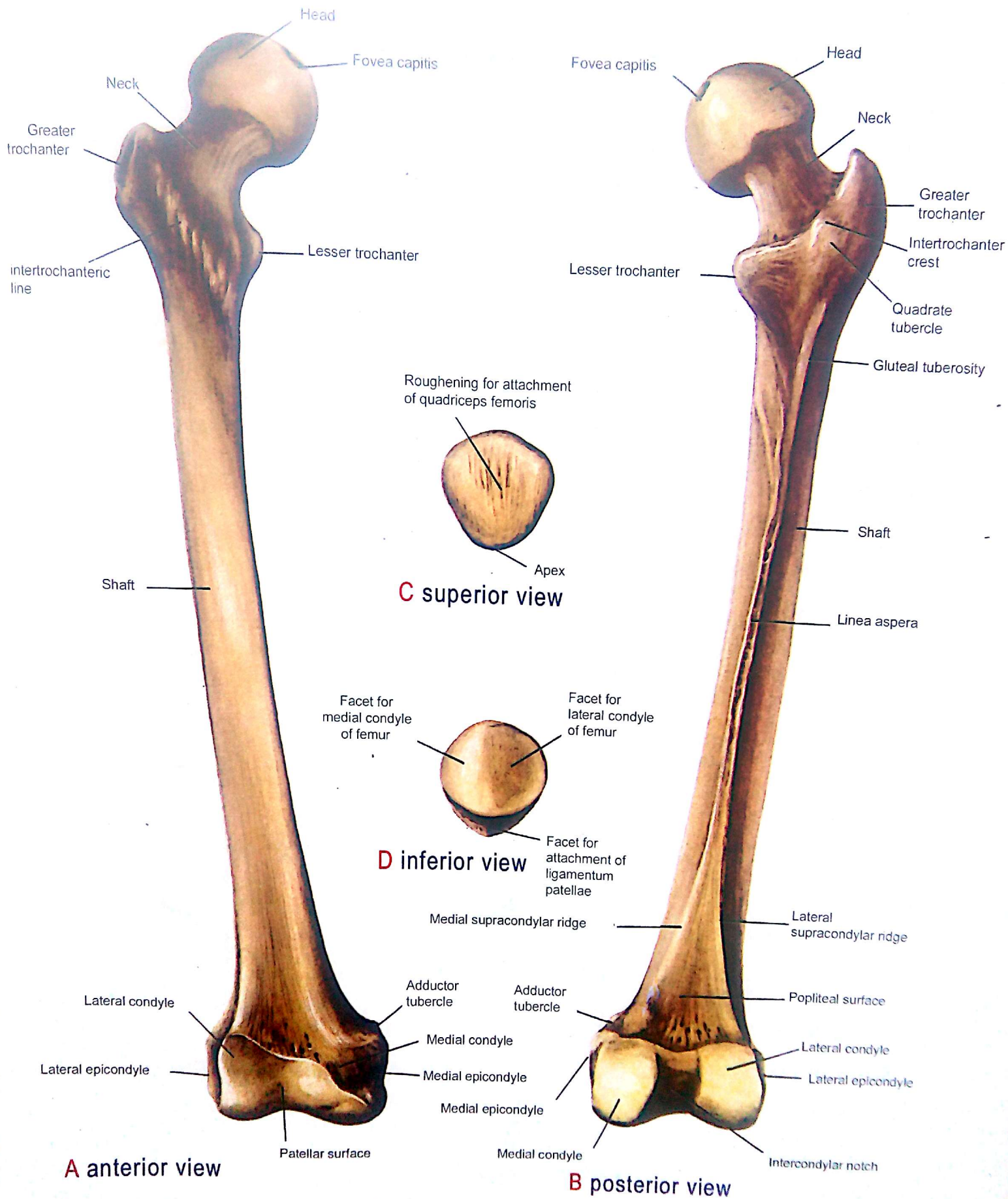


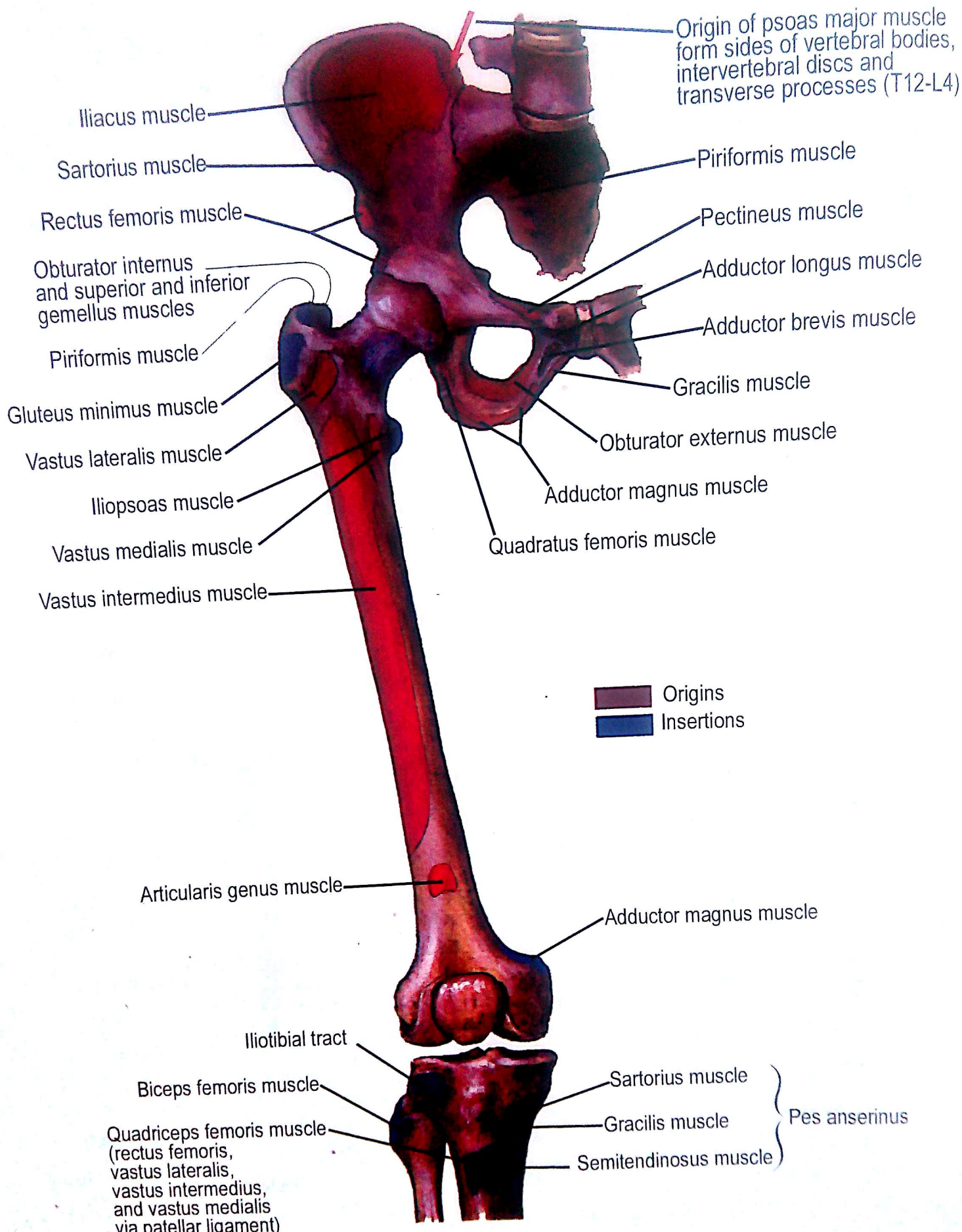
Lateral view



- Ilium
- Ischium
- Pubis

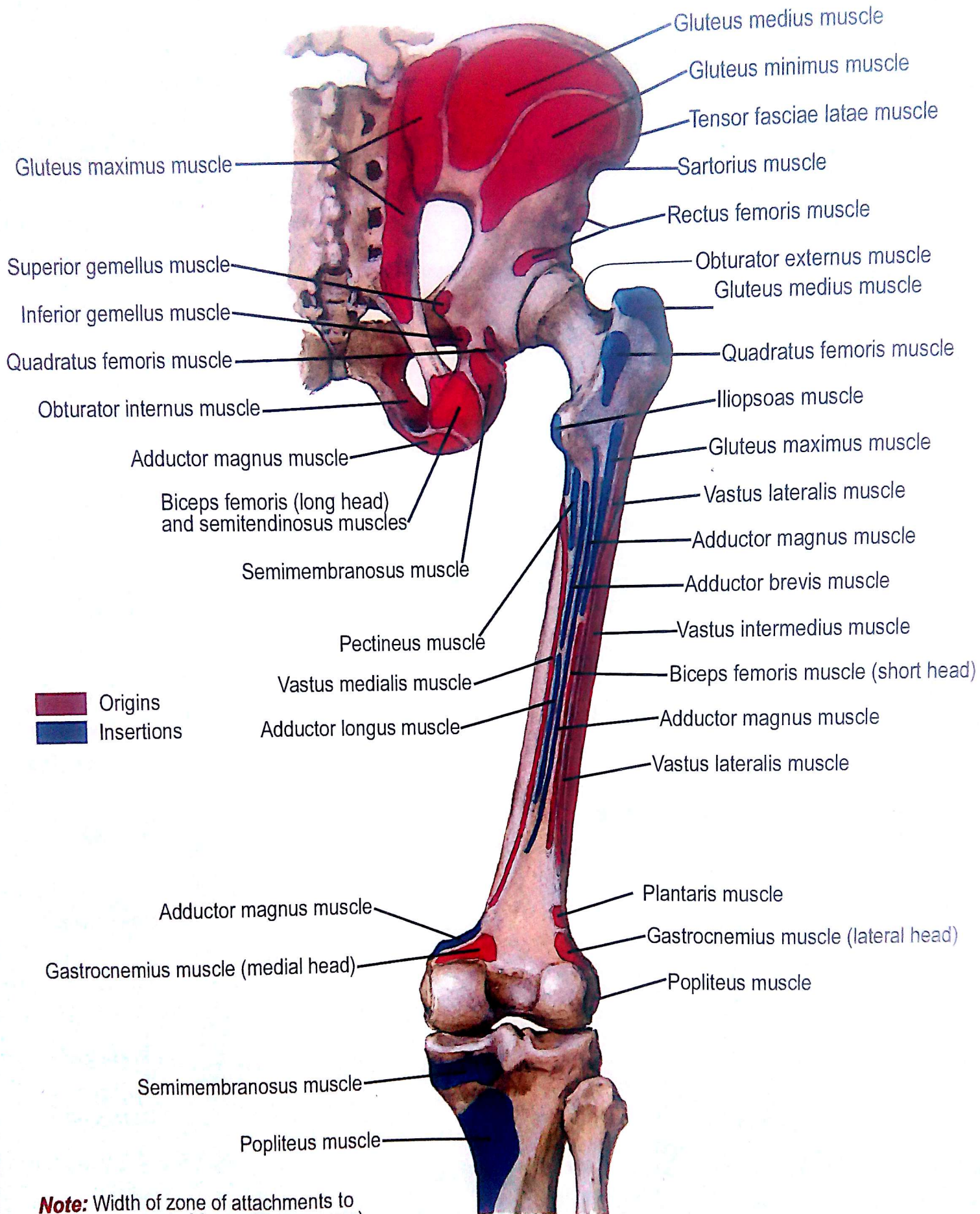
Hip (Coxal) Bone





Anterior view

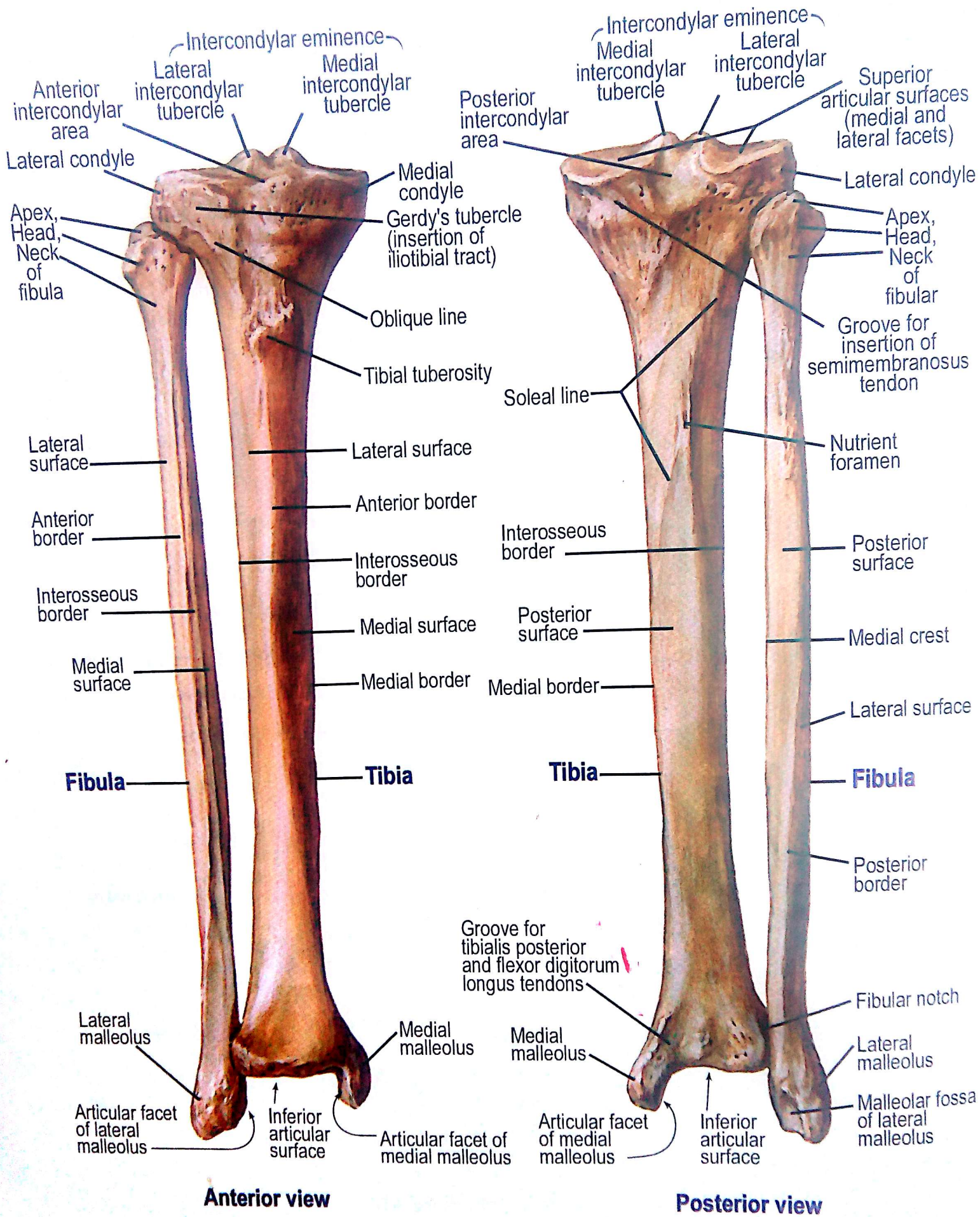
Bony Attachments of Muscles of Hip and Thigh



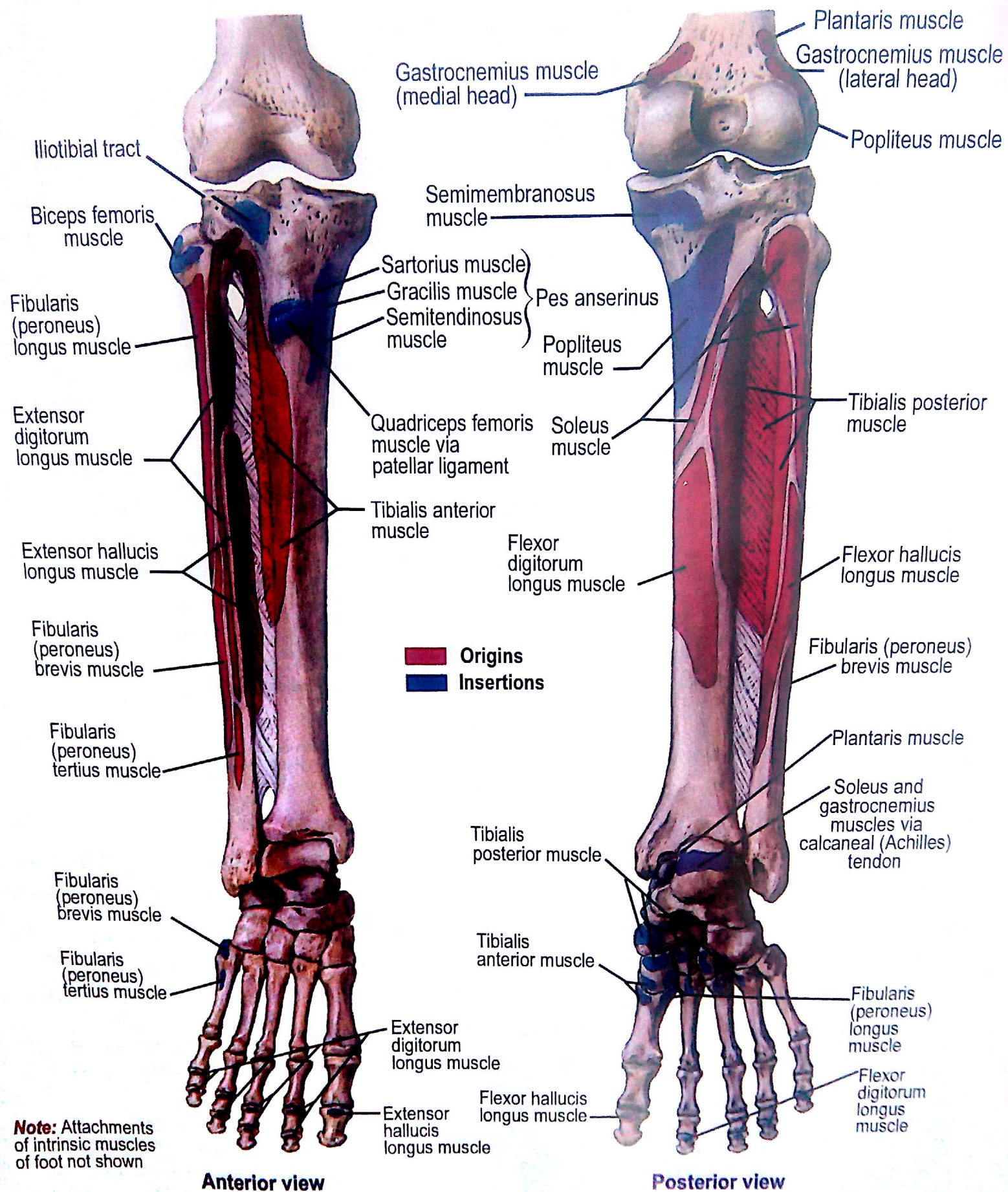
Note: Width of zone of attachments to posterior aspect of femur (linea aspera) is greatly exaggerated

Posterior view

Bony Attachments of Muscles of Hip and Thigh

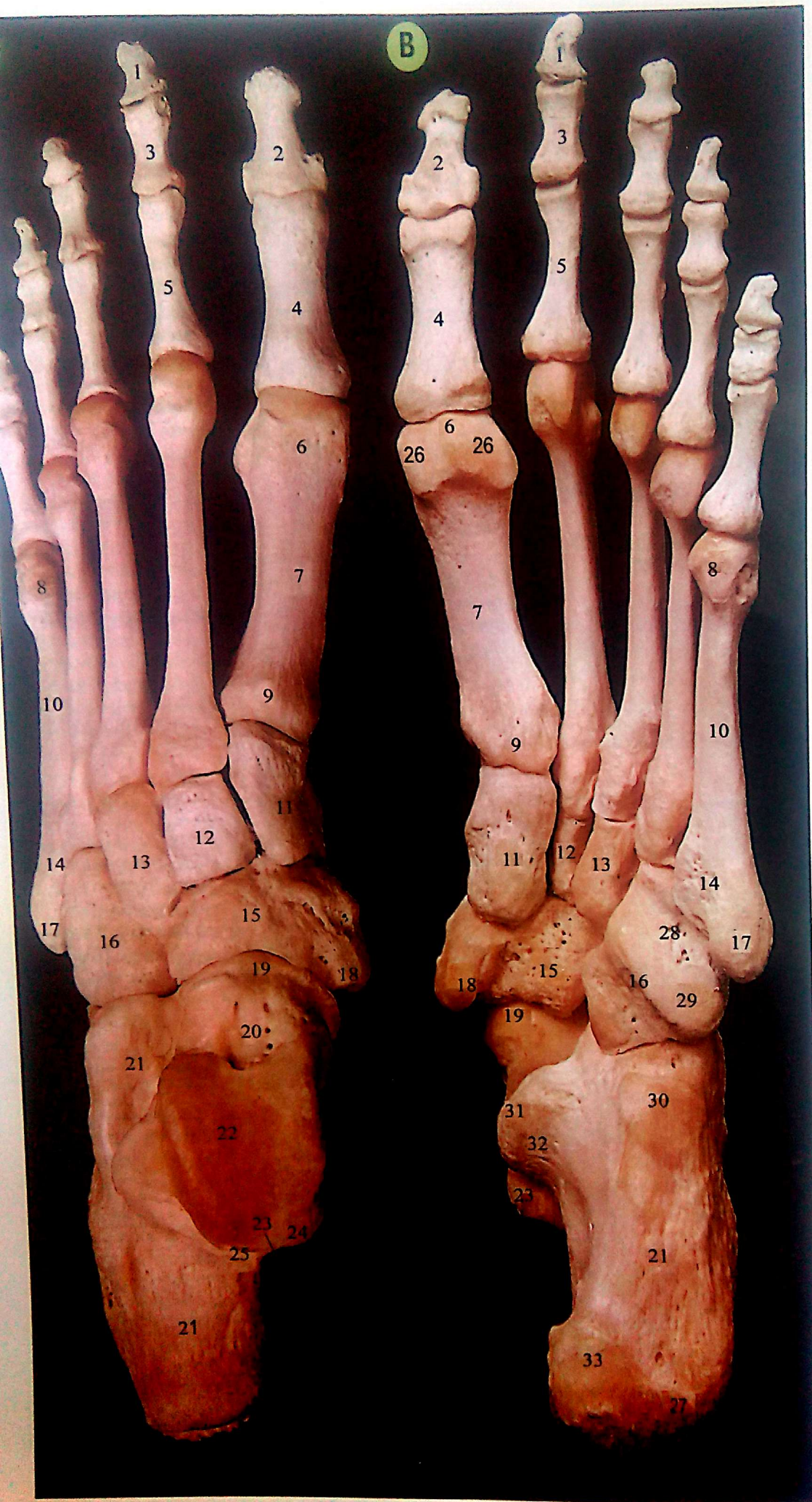


Right Tibia and Fibula

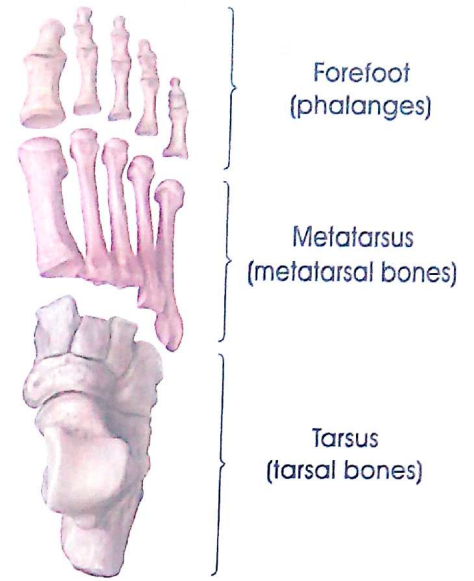
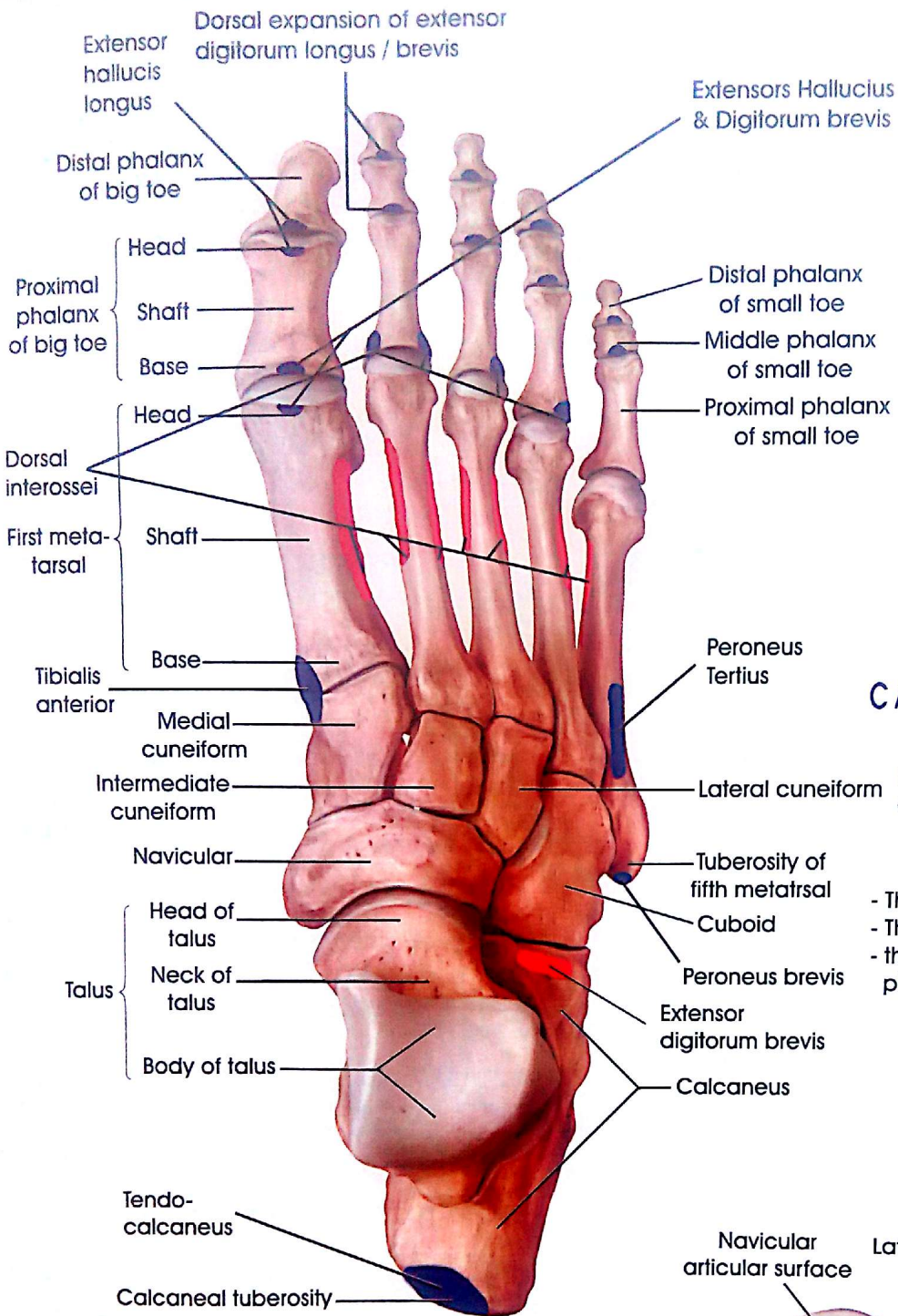


Attachments of Muscles of Leg

Bones of the left foot,
A from above (dorsum),
B from below (plantar surface)



- 1 Distal phalanx of second toe
- 2 Distal phalanx of great toe
- 3 Middle phalanx of second toe
- 4 Proximal phalanx of great toe
- 5 Proximal phalanx of second toe
- 6 Head of first metatarsal
- 7 Shaft of first metatarsal
- 8 Head of fifth metatarsal
- 9 Base of first metatarsal
- 10 Shaft of fifth metatarsal
- 11 Medial cuneiform
- 12 Intermediate cuneiform
- 13 Lateral cuneiform
- 14 Base of fifth metatarsal
- 15 Navicular
- 16 Cuboid
- 17 Tuberosity of base of fifth metatarsal
- 18 Tuberosity of navicular
- 19 Head of talus
- 20 Neck of talus
- 21 Calcaneus
- 22 Trochlear surface of body of talus
- 23 Groove on talus for flexor hallucis longus
- 24 Medial tubercle of talus
- 25 Lateral tubercle of talus
- 26 Grooves for sesamoid bones in flexor hallucis brevis
- 27 Lateral process of calcaneus
- 28 Groove on cuboid for peroneus longus
- 29 Tuberosity of cuboid
- 30 Anterior tubercle of calcaneus
- 31 Sustentaculum tali of calcaneus
- 32 Groove on calcaneus for flexor hallucis longus
- 33 Medial process of calcaneus



C Anatomical subdivisions of the pedal skeleton

Right foot, dorsal view. In the nomenclature of descriptive anatomy, the skeletal element of the foot are subdivided into three adjoining segments:

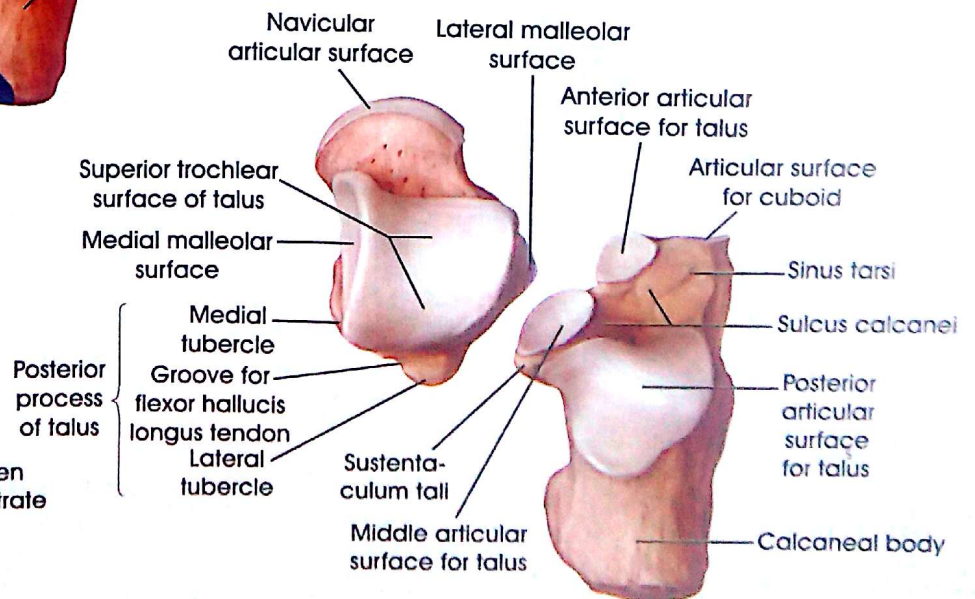
- The tarsus, composed of seven bones
- The metatarsus, composed of five bones
- the forefoot (antetarsus), composed of 14 phalanges

A The bones of the right foot Dorsal view

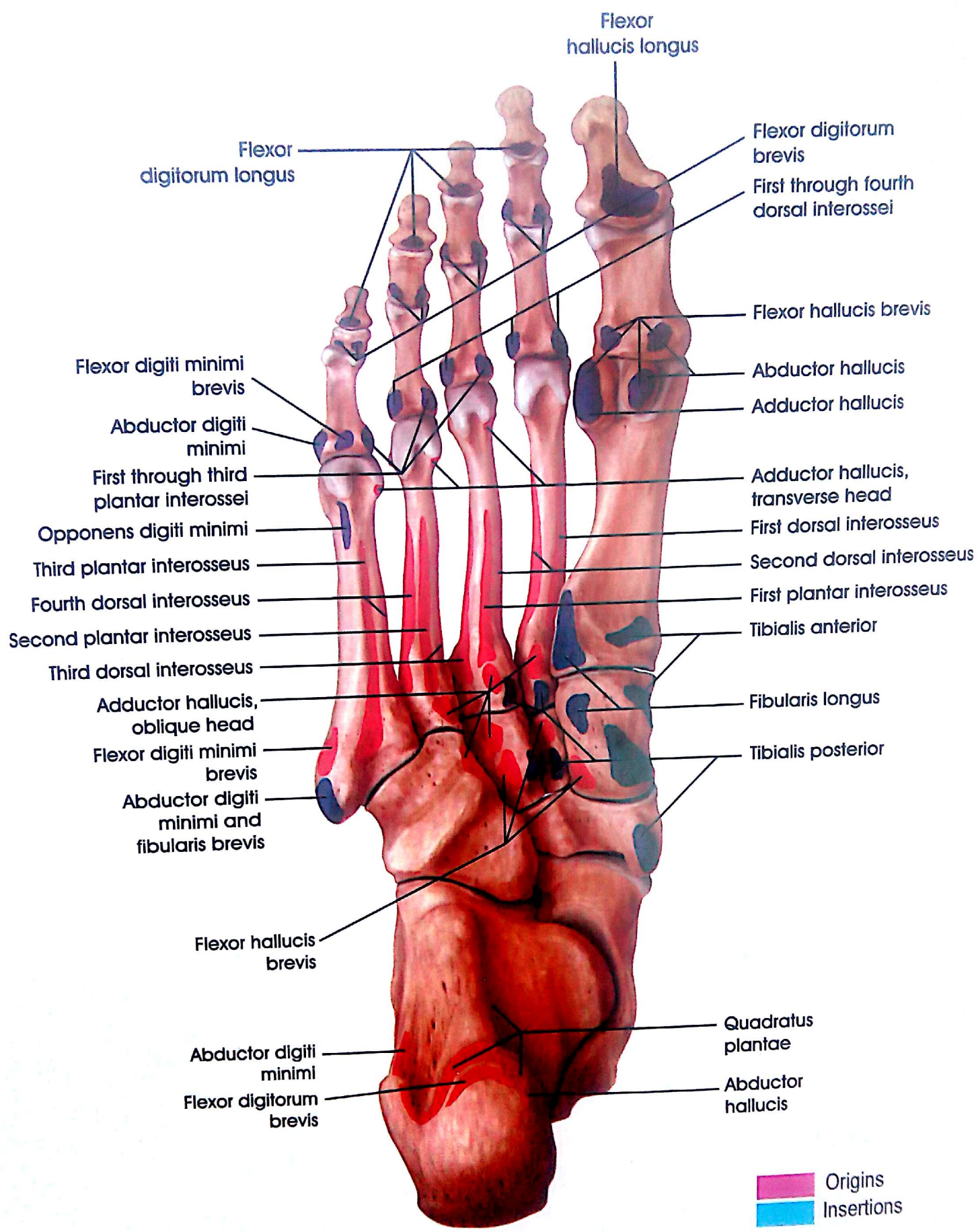
Origins
 Insertions

B The right talus and calcaneus

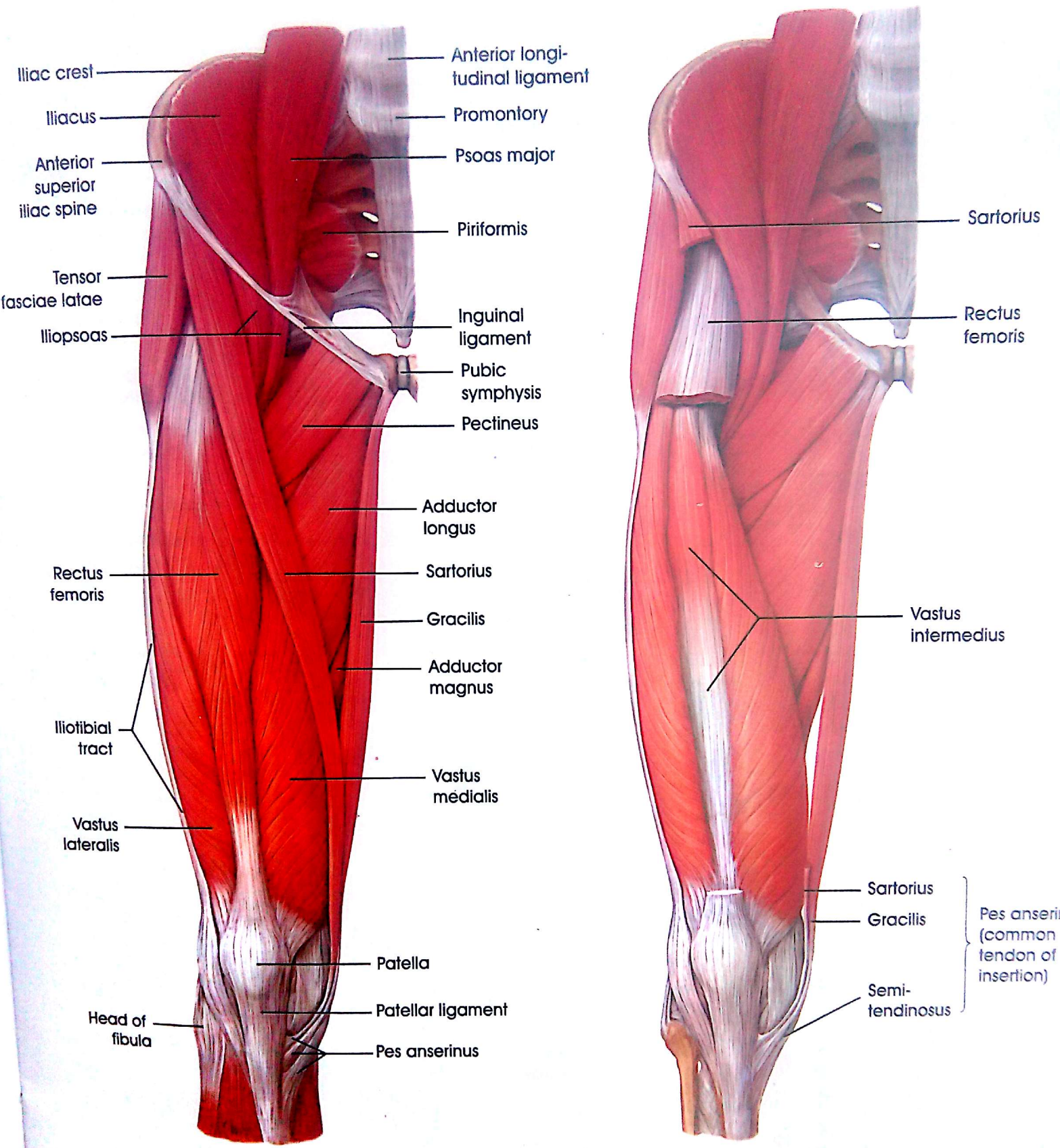
Dorsal view. The two tarsal bones have been separated at the subtalar joint to demonstrate their articular surfaces.



The Bones of the Foot from the dorsal and Plantar Views

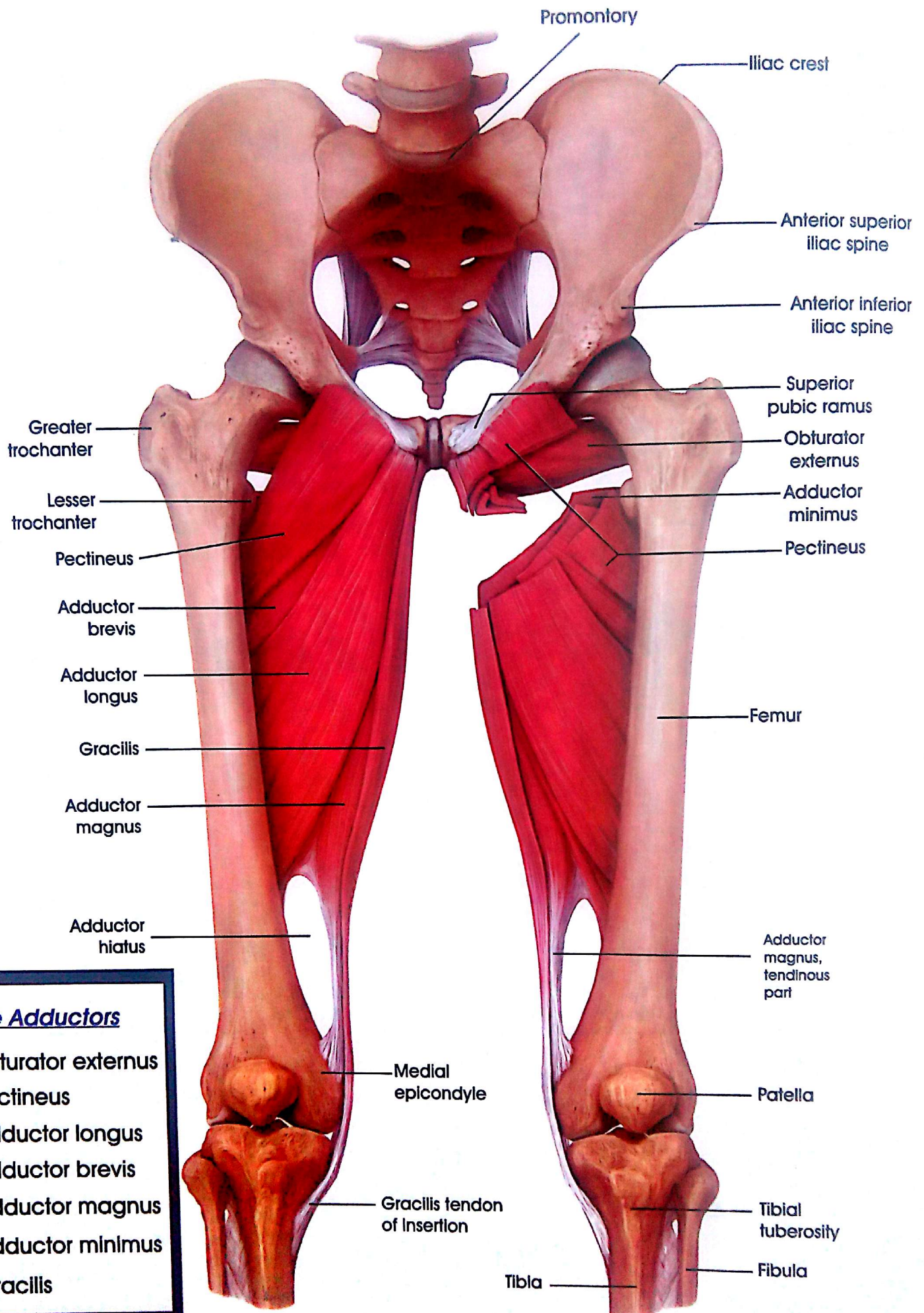


Muscle Origins and Insertions on the Plantar View of the Right Foot



Anterior View

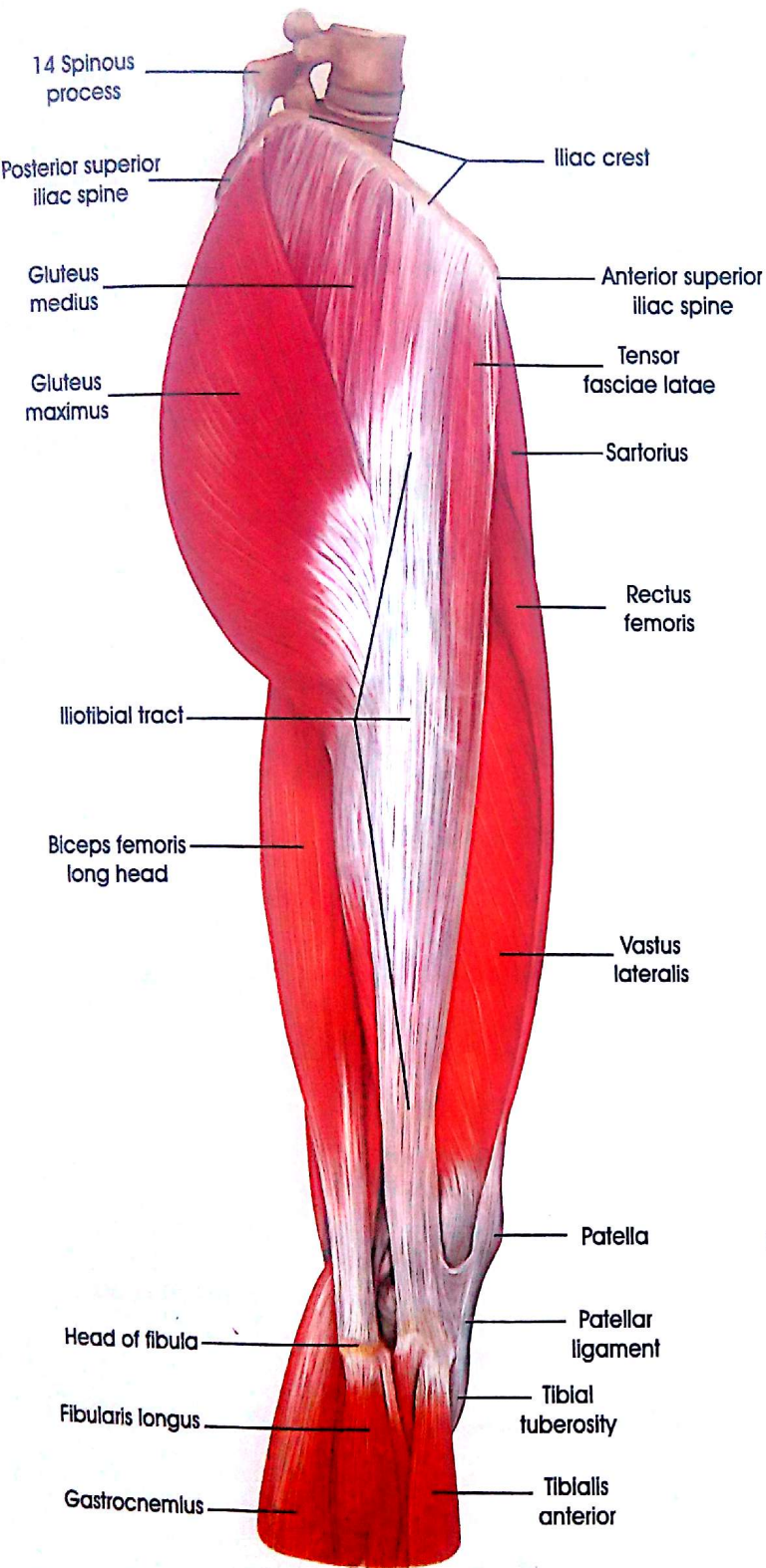
The Muscles of the Right Thigh, Hip, and Gluteal Region



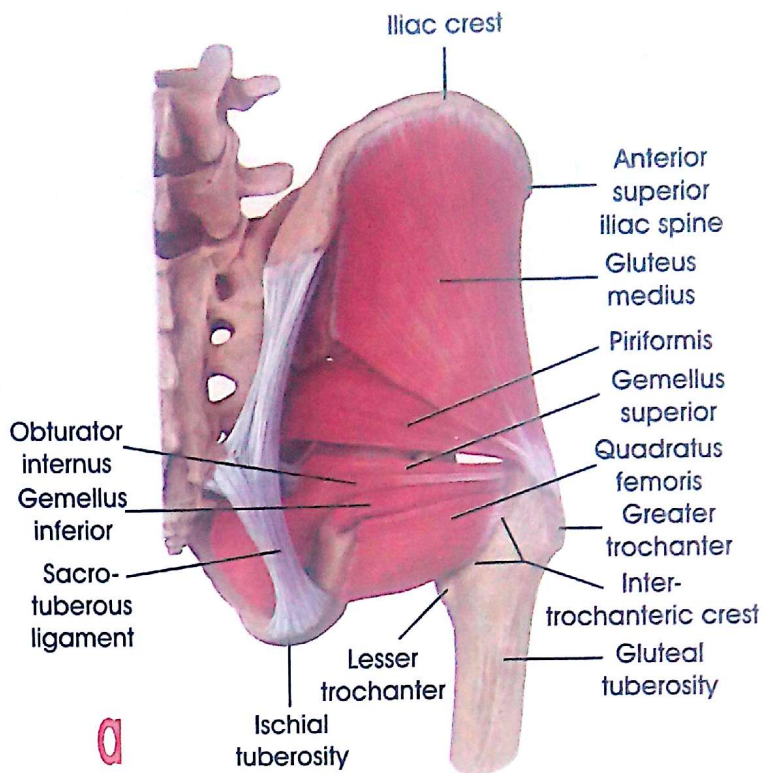
The Adductors

- 1) Obturator externus
- 2) Pectineus
- 3) Adductor longus
- 4) Adductor brevis
- 5) Adductor magnus
- 6) Adductor minimus
- 7) Gracilis

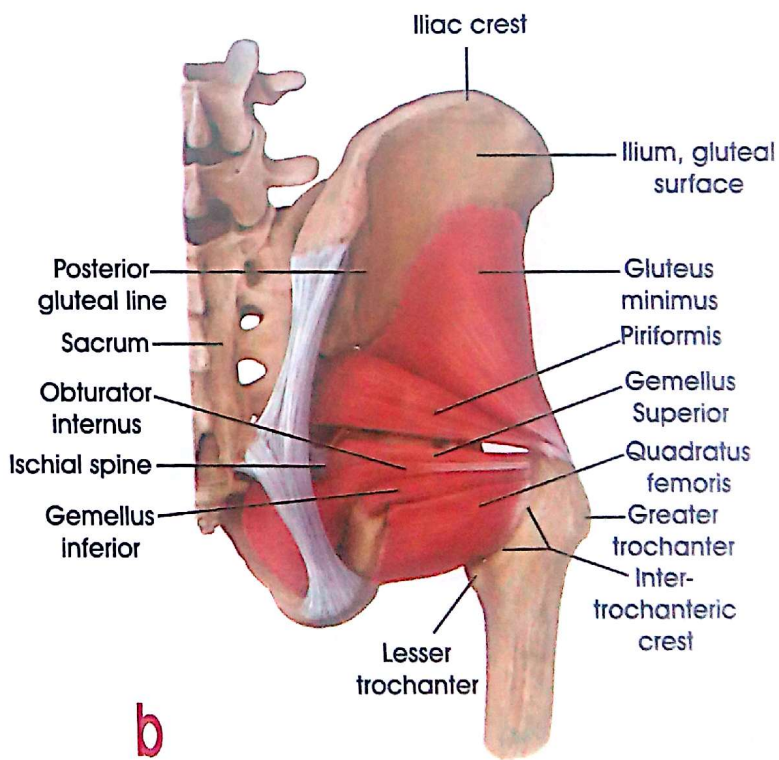
The Adductors



**The Muscles of Right Thigh , Hip and Gluteal Region
(lateral View)**



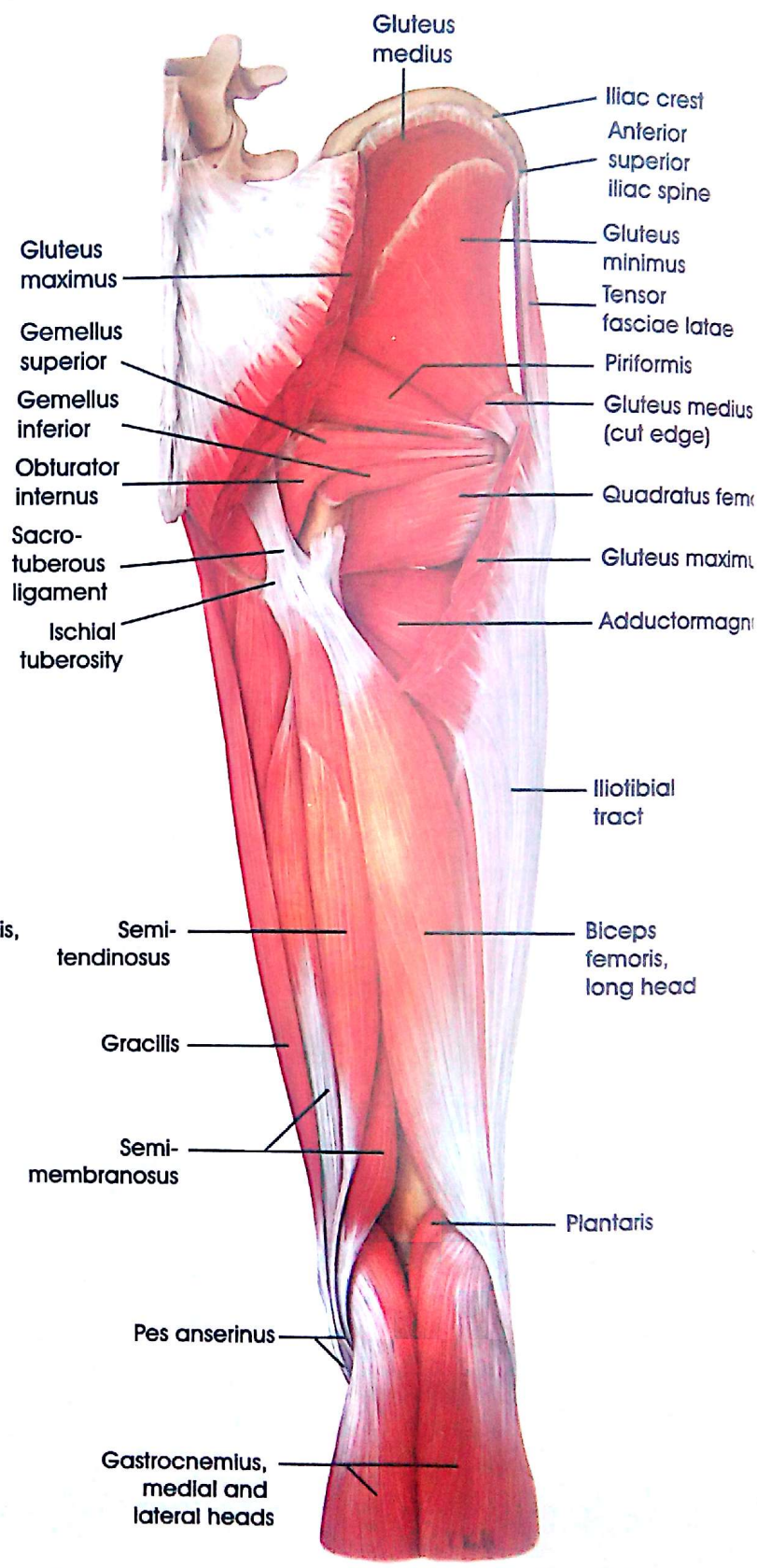
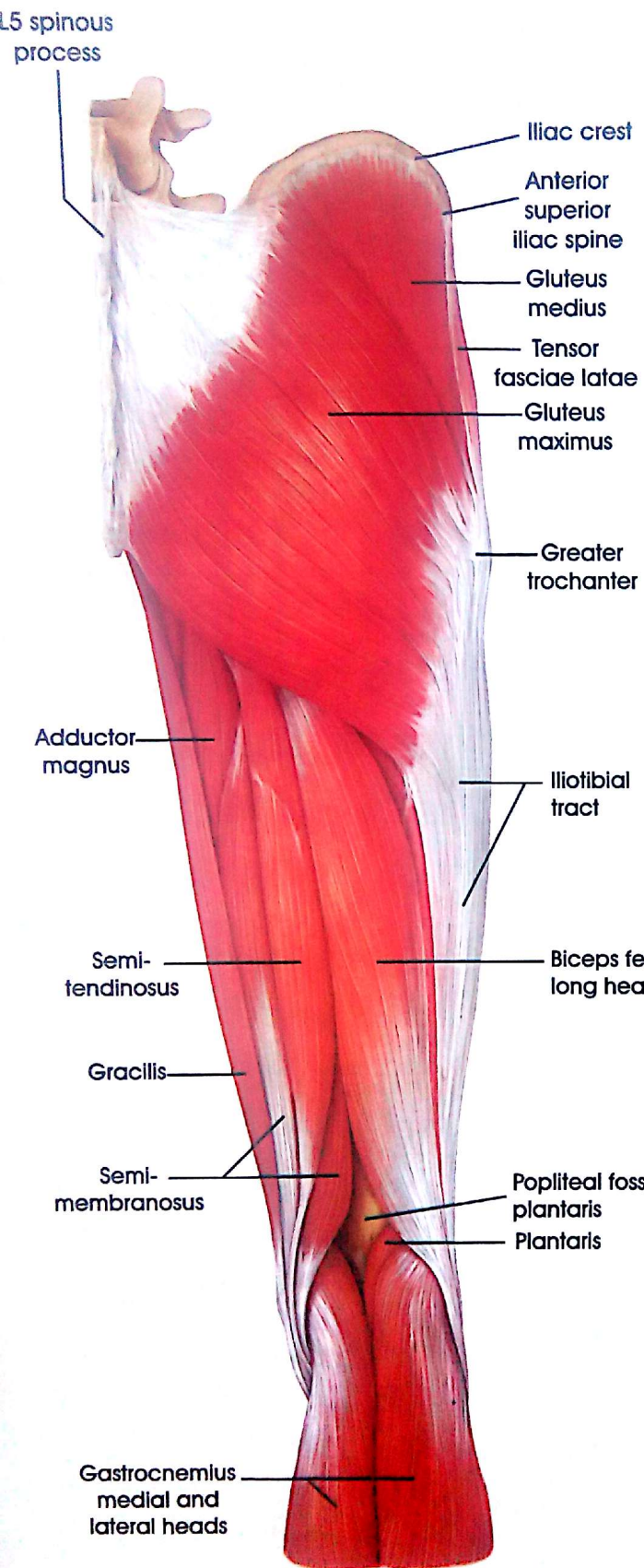
a



b

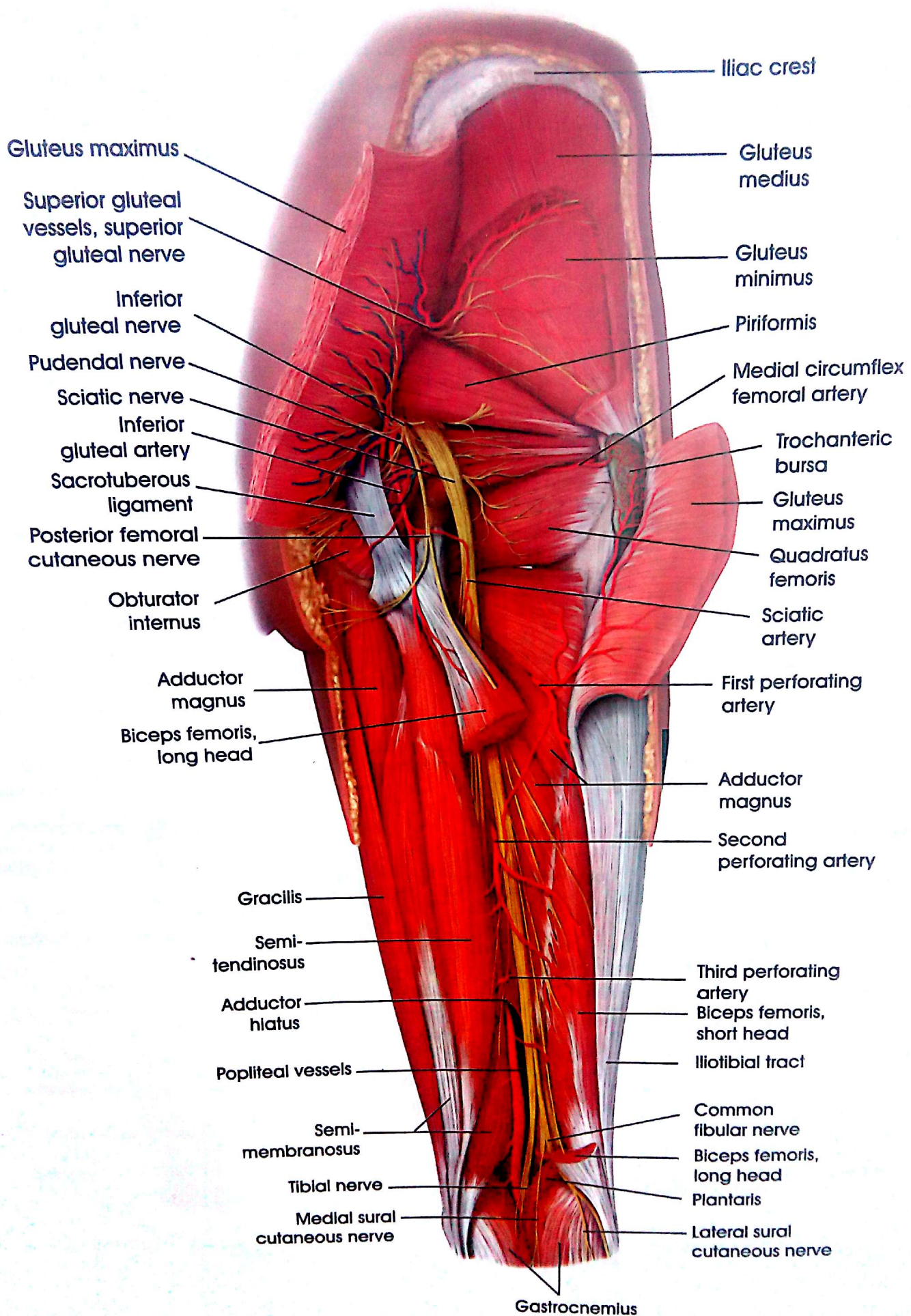
**Gluteal Muscles
(Deep Layer)**

Muscles of Back of Thigh and Gluteal Region

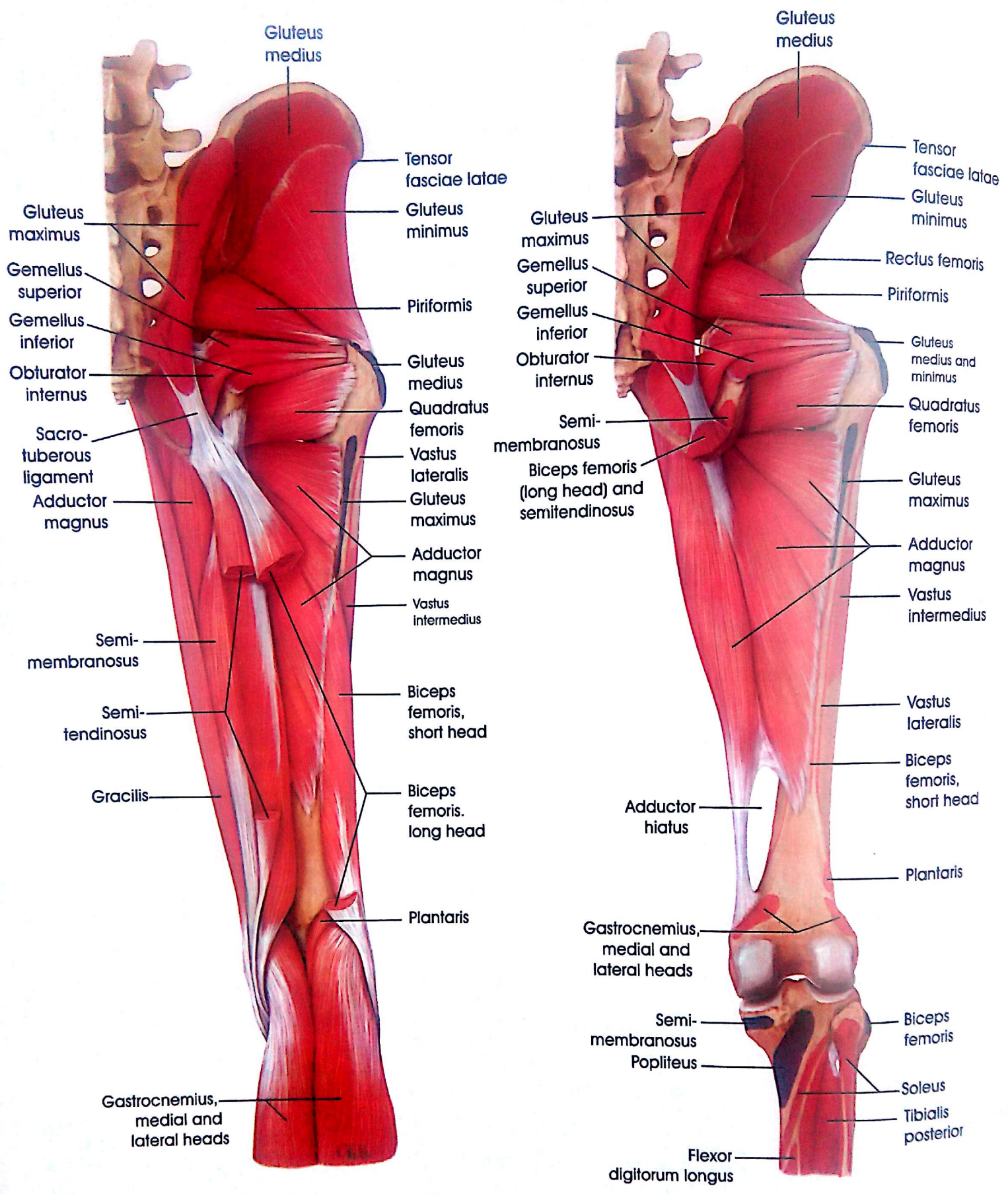


Posterior View

Muscles of the back of the Thigh, Hip, Gluteal and Popliteal Region

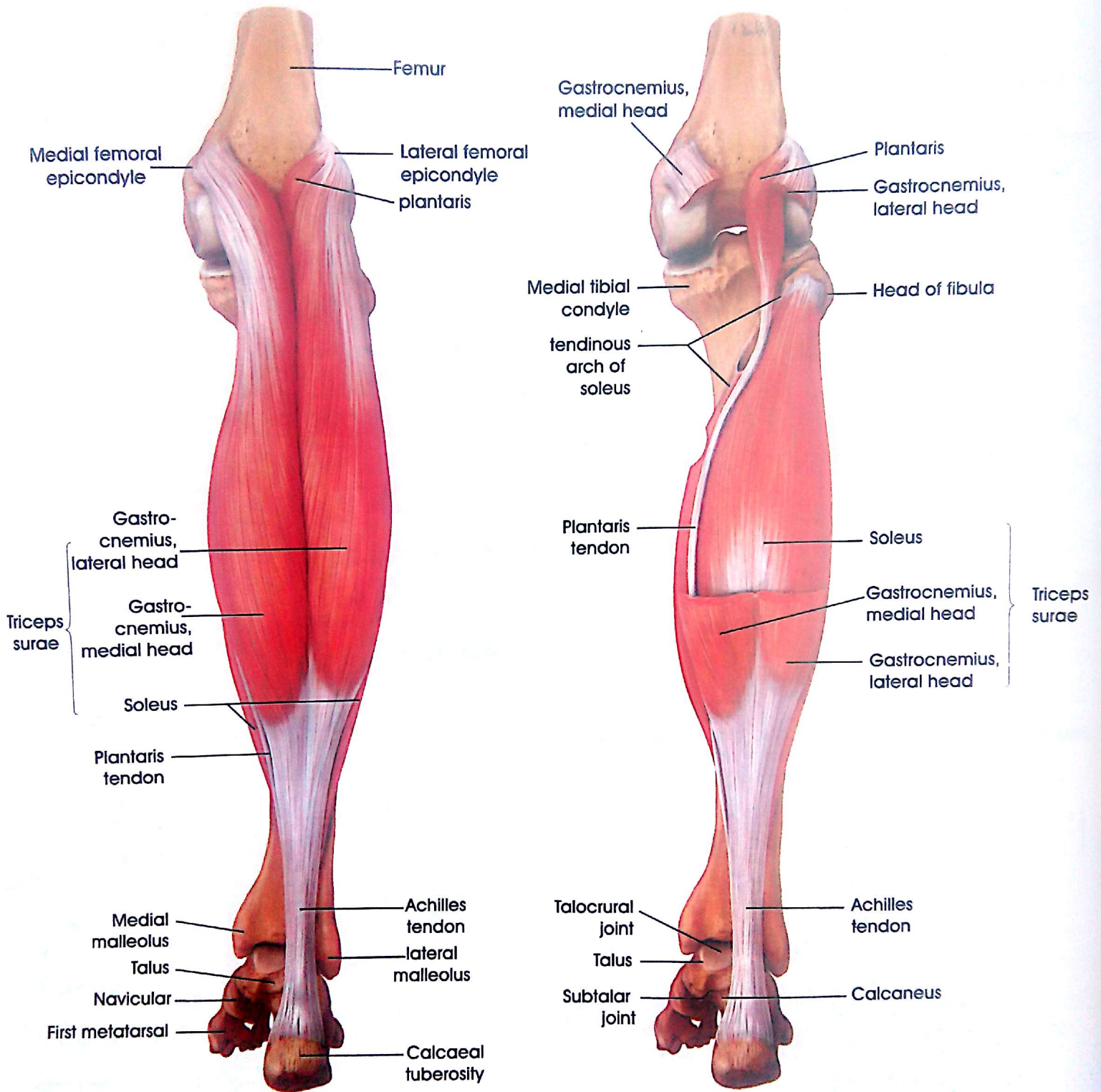


Muscles of back of the Thigh , Gluteal and Popliteal Region



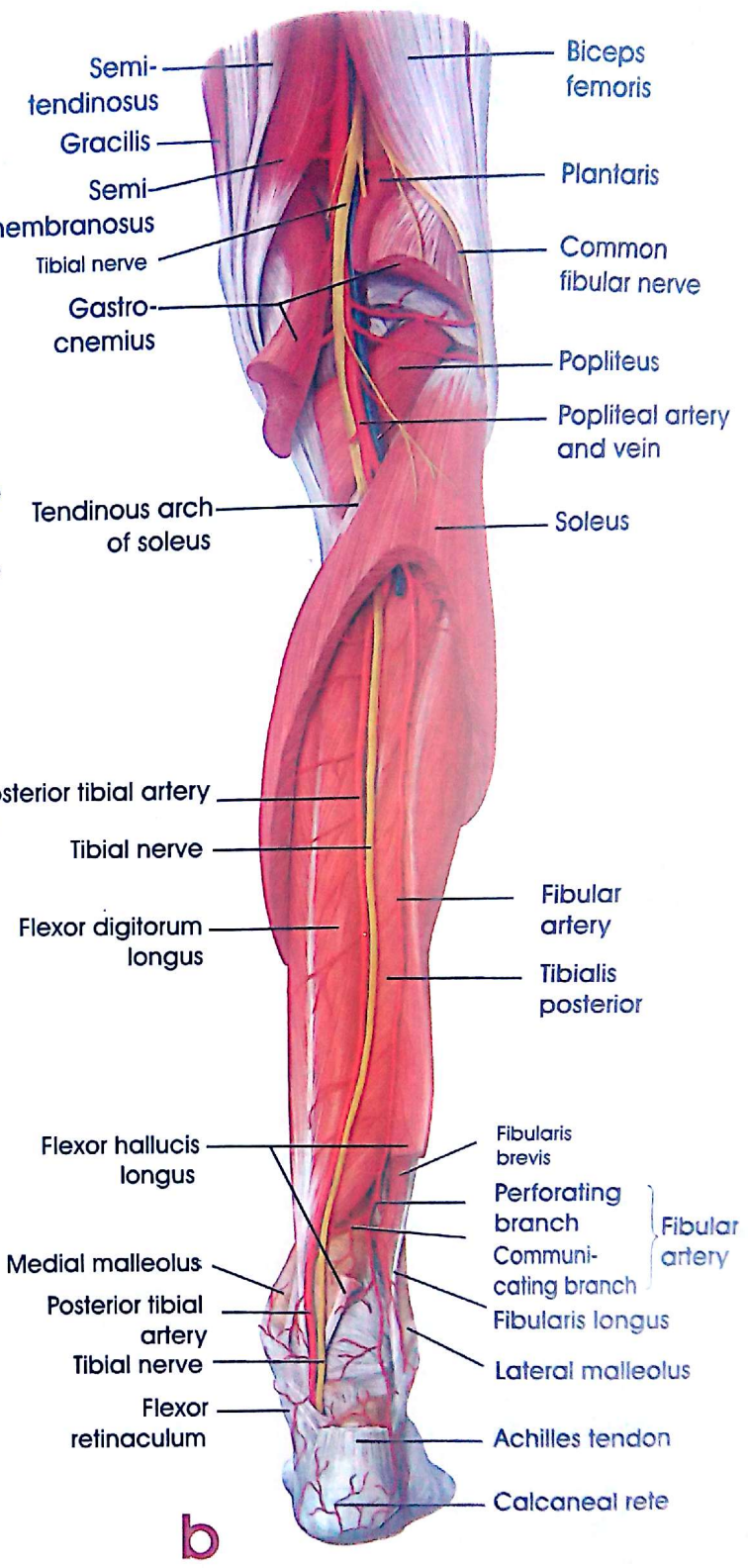
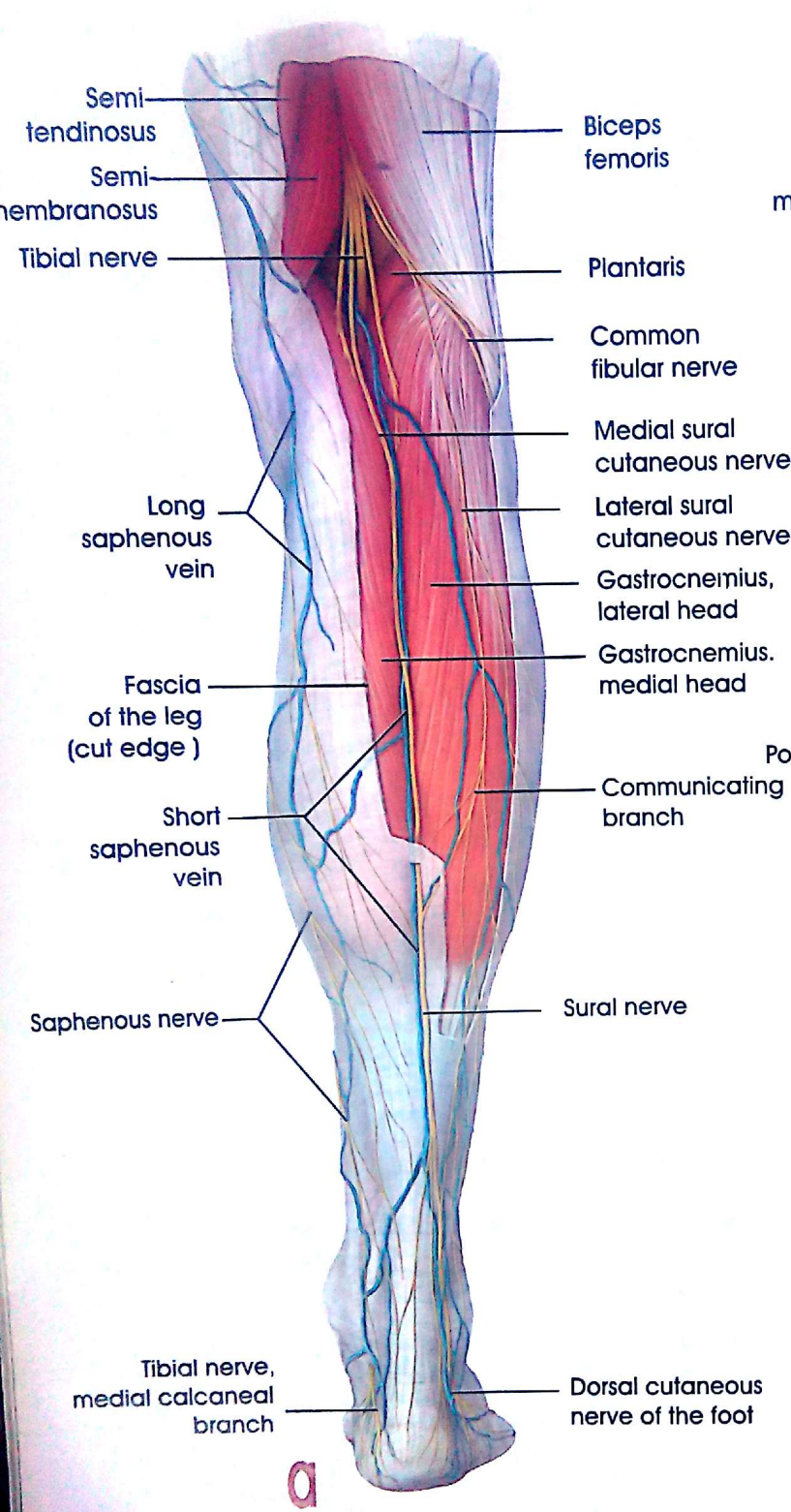
Origins and Insertions

The Muscles of the Thigh, Hip, and Gluteal Region



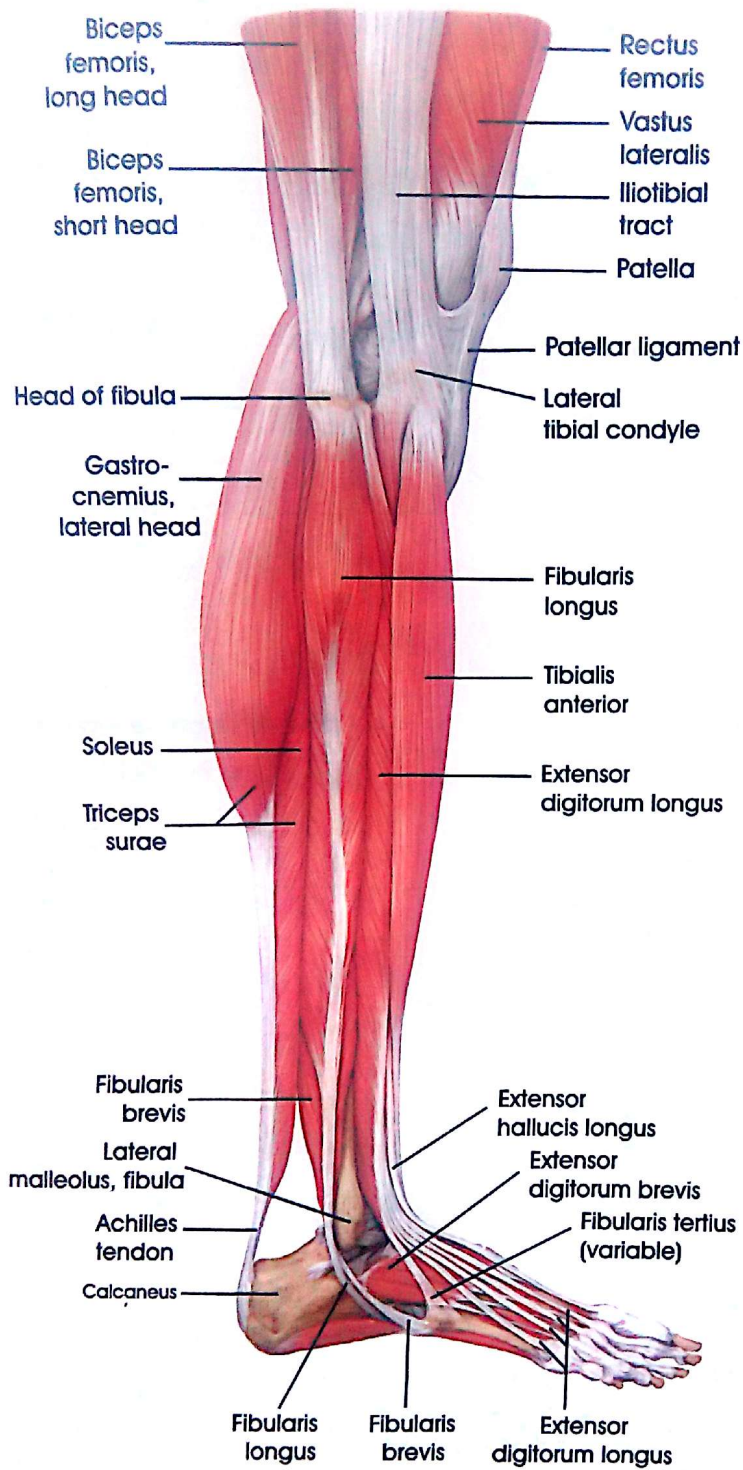
The Superficial Flexors (triceps surae and plantaris)

Back of the Leg



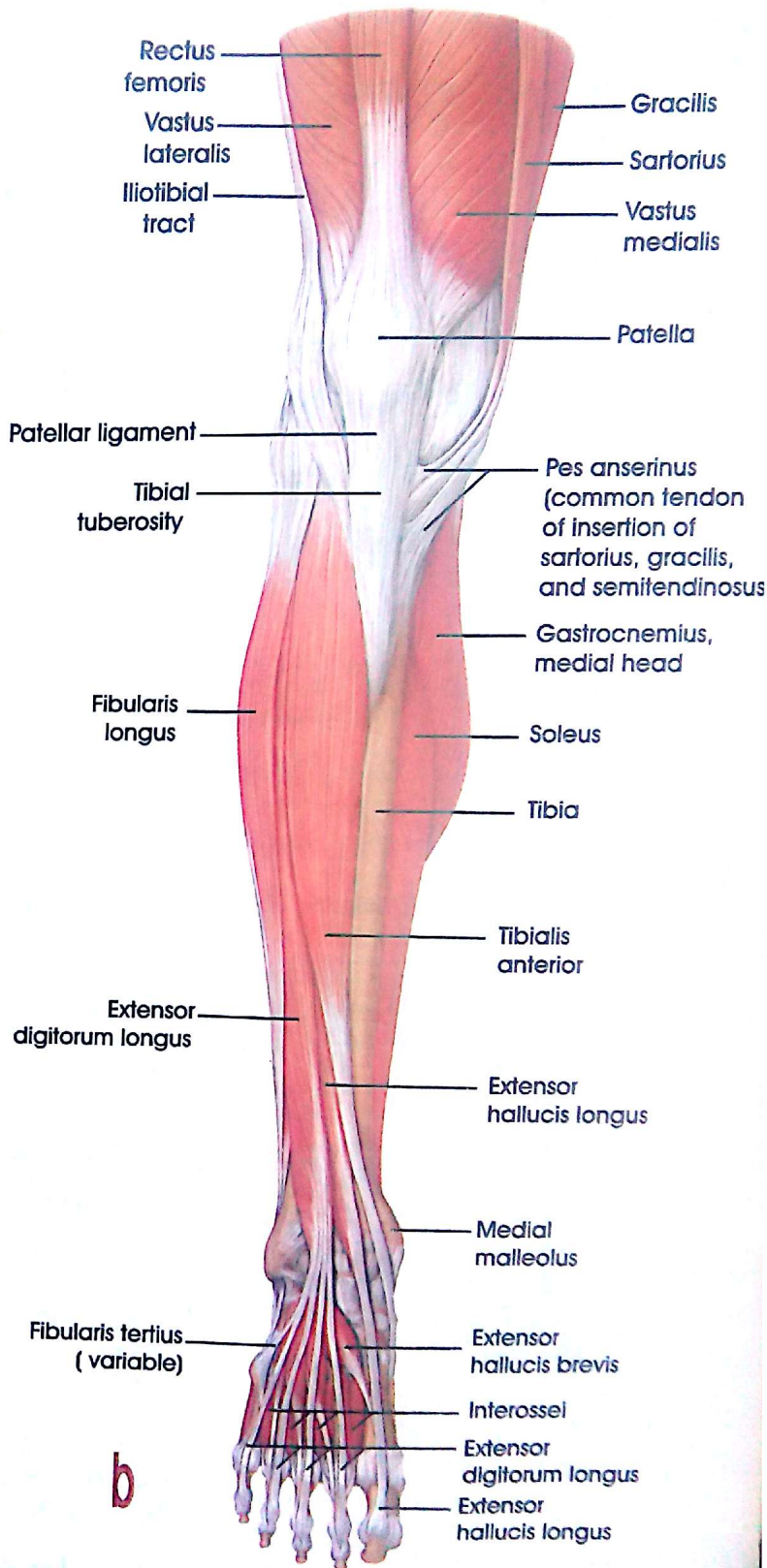
The Neurovascular structures in the Superficial and Deep posterior compartments

Back of the Leg and Tarsal Tunnel



a

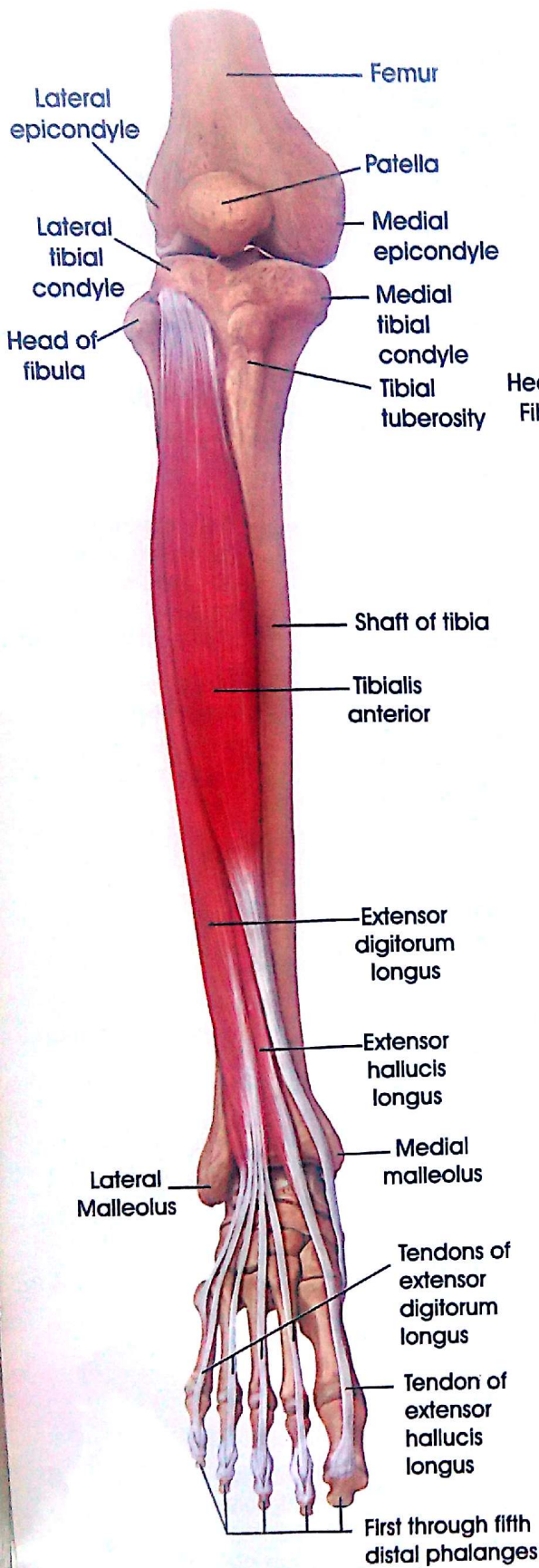
Lateral View



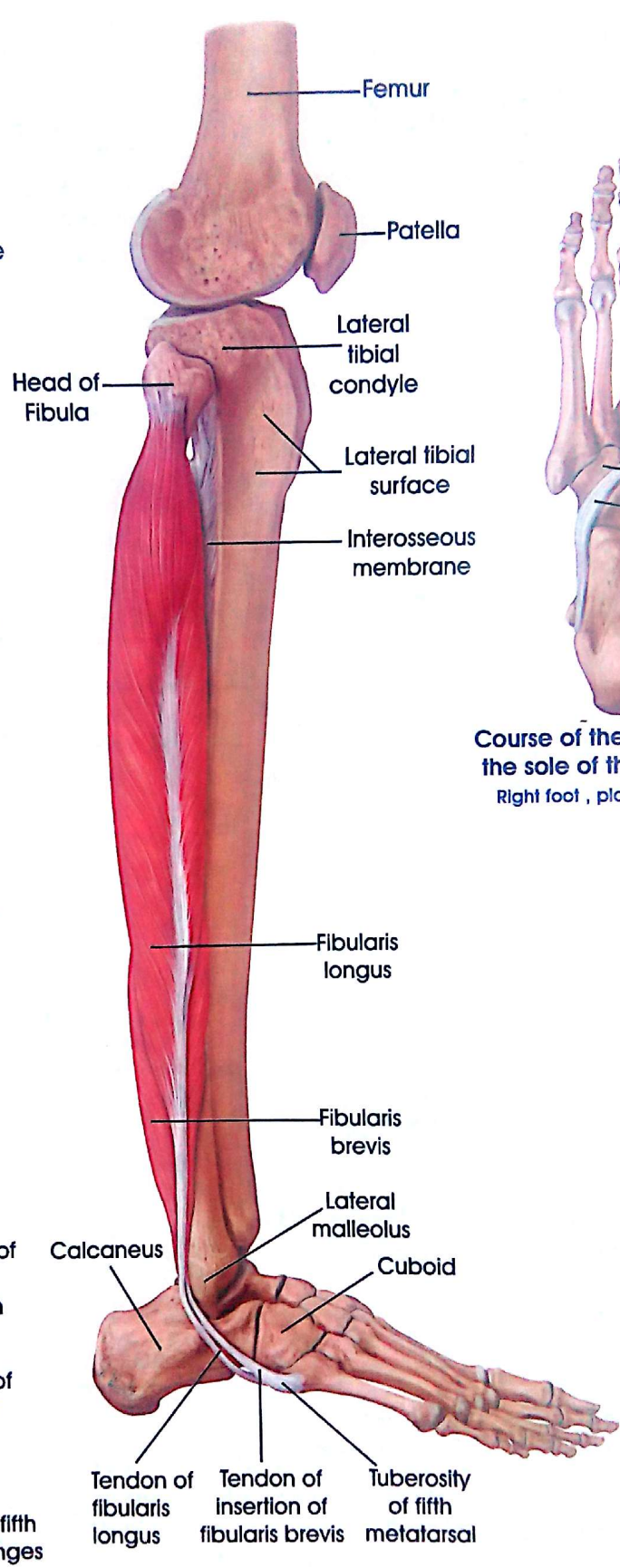
b

Anterior View

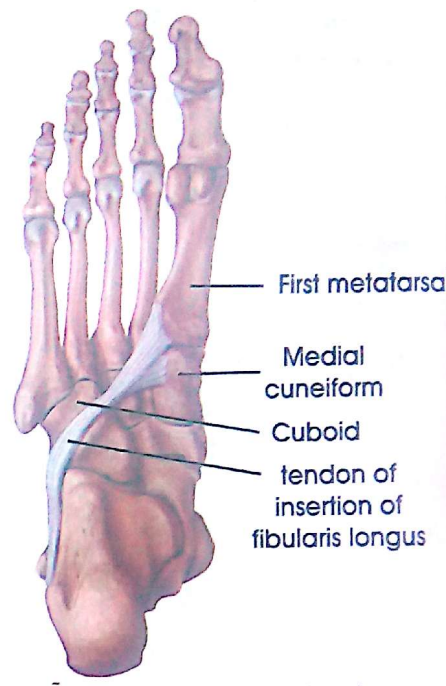
The Muscles of the Leg from the Lateral and Anterior View



The Anterior Compartment
 (Tibialis anterior, extensor digitorum longus, and extensor hallucis longus)

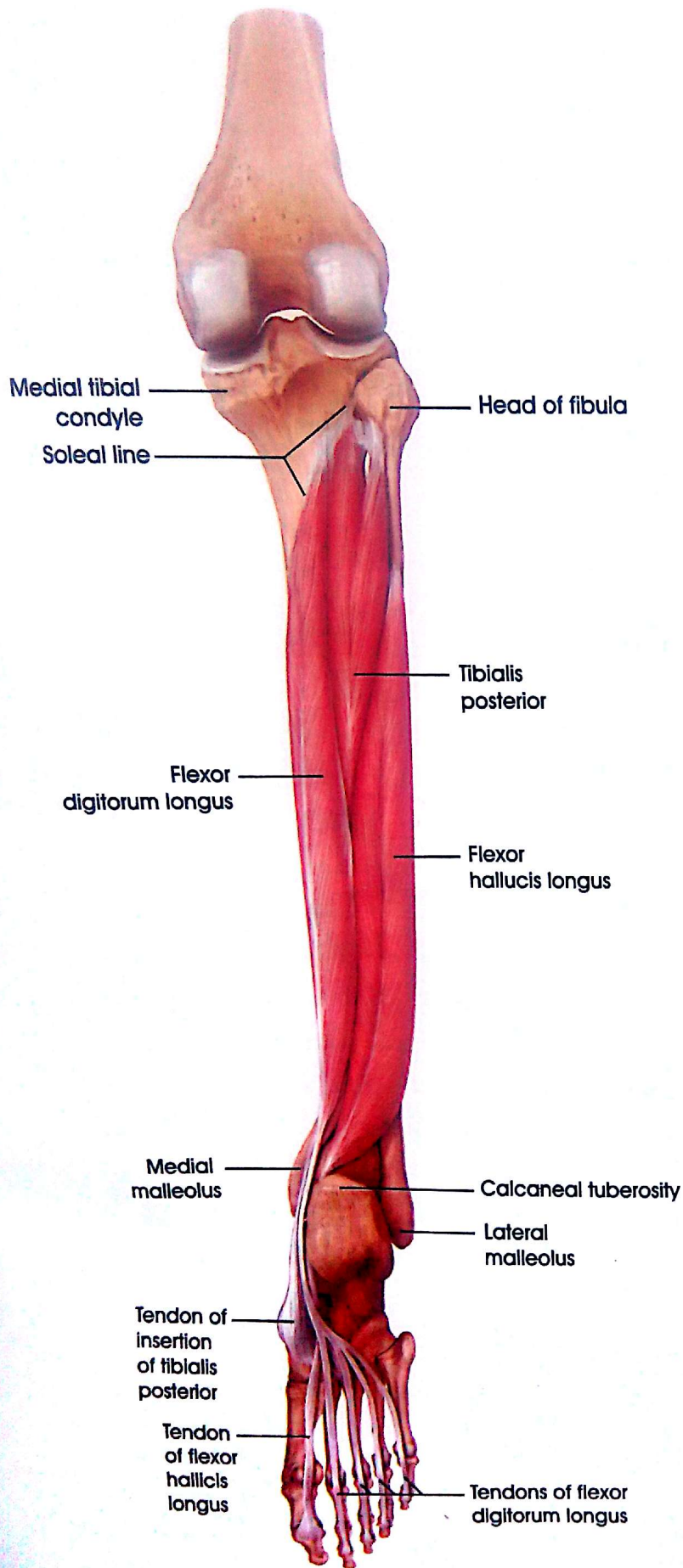


The Lateral Compartment
 (Fibularis longus and brevis)

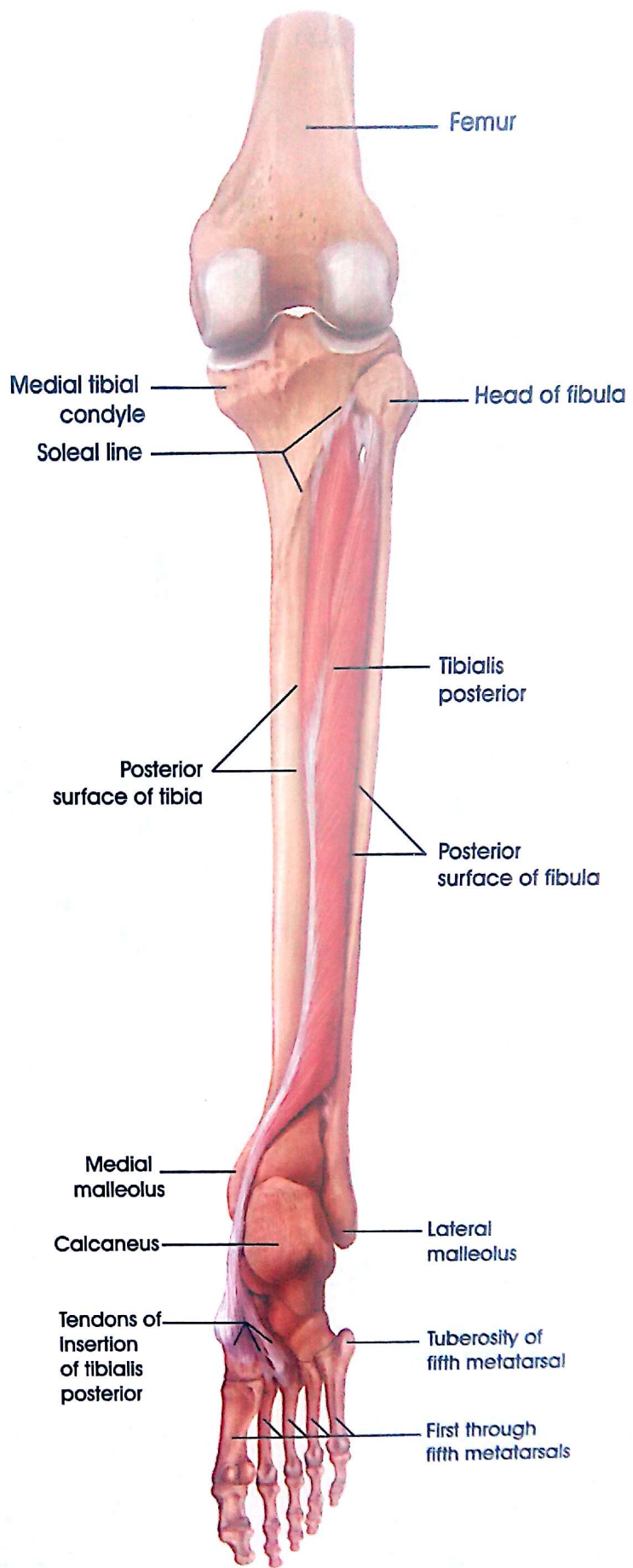


Course of the fibularis longus tendon on the sole of the foot
 Right foot, plantar view.

Anterior and Lateral compartment of the Leg

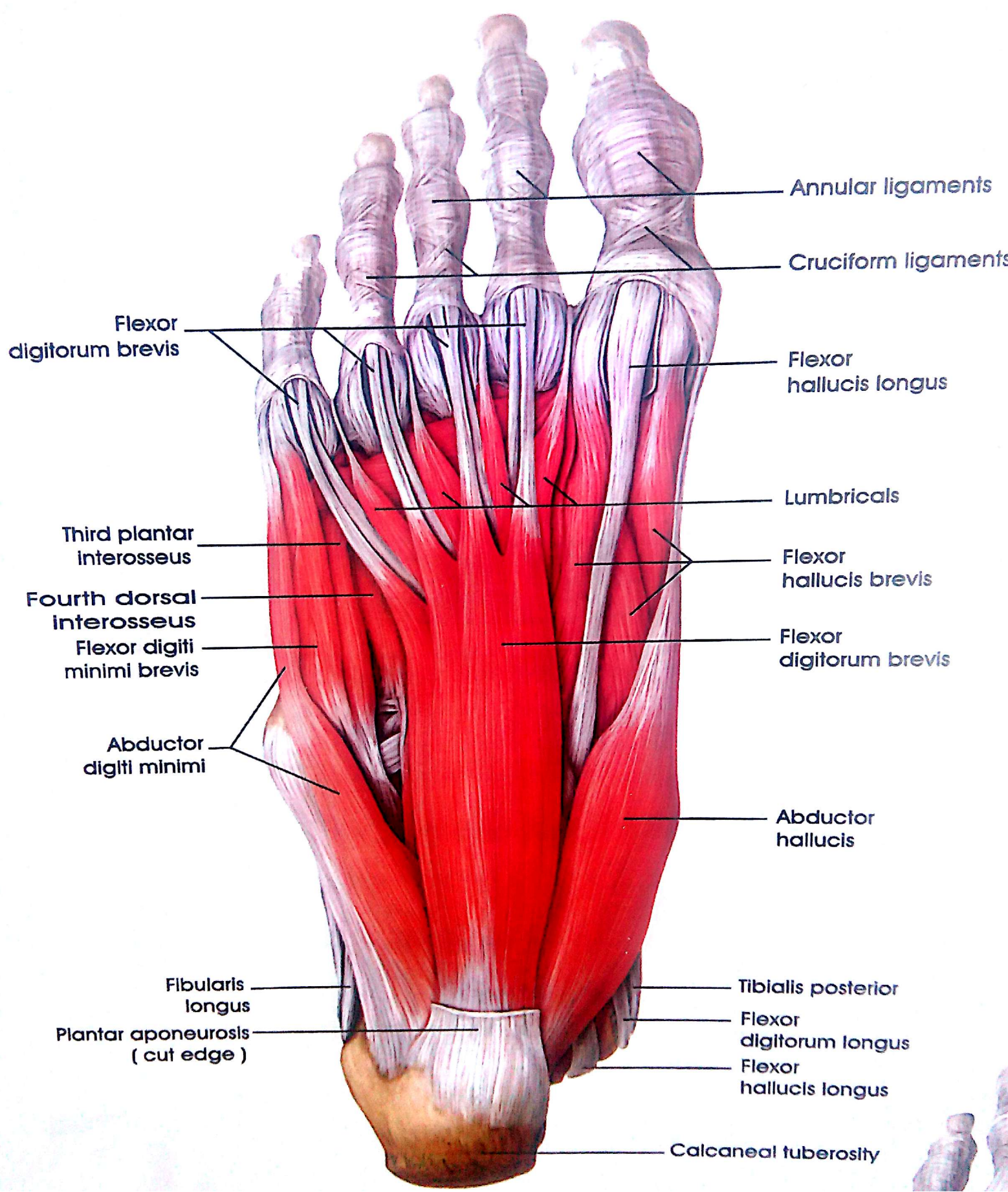


Tibialis posterior, flexor digitorum longus, and Flexor hallucis longus



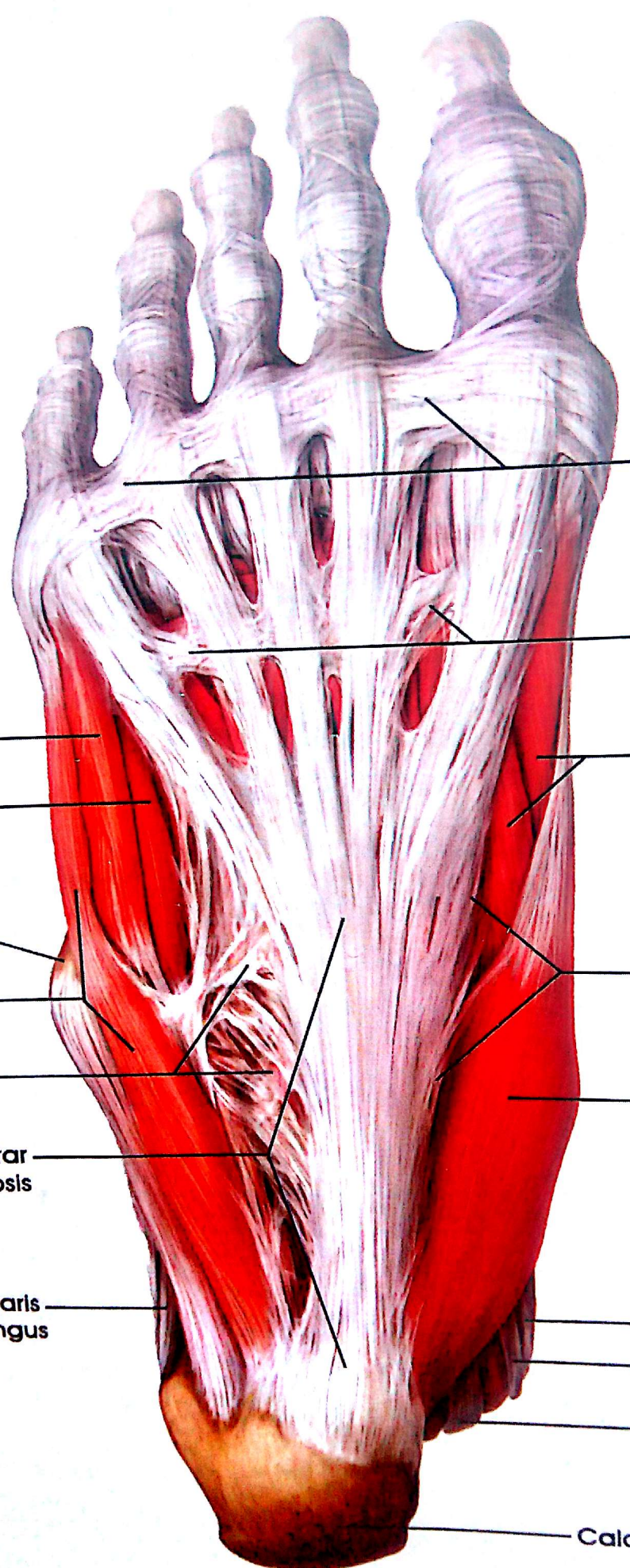The Tibialis posterior

Deep Flexors of the Leg



Tibialis posterior
 Flexor digitorum longus
 Flexor hallucis longus

Calcaneal tuberosity



Superficial transverse metacarpal ligament

Transverse fascicles

Flexor hallucis brevis

Flexor digiti minimi brevis
 Third plantar interosseus

Medial plantar septum

Tuberosity of fifth metatarsal
 Abductor digiti minimi
 Lateral plantar septum

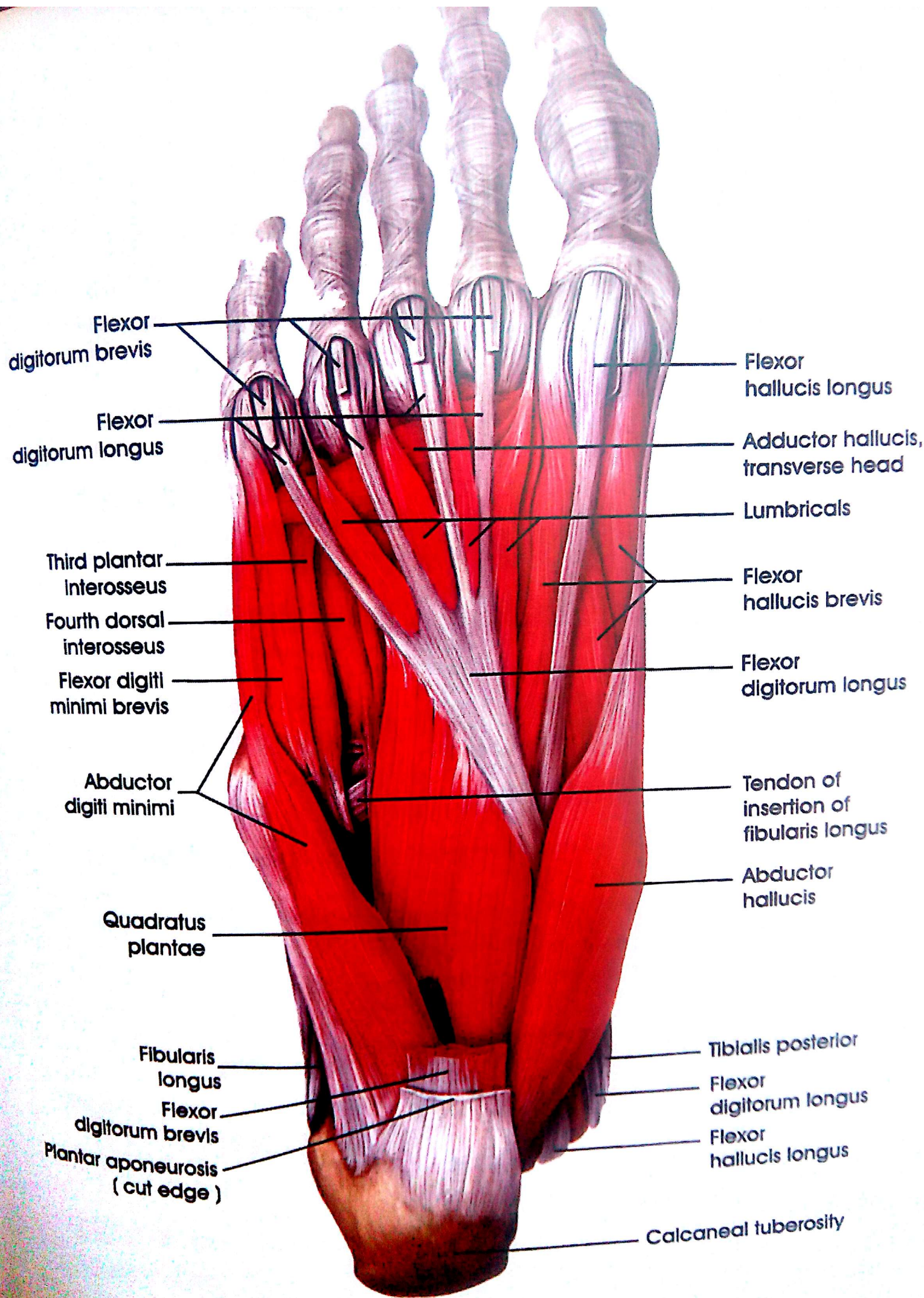
Abductor hallucis

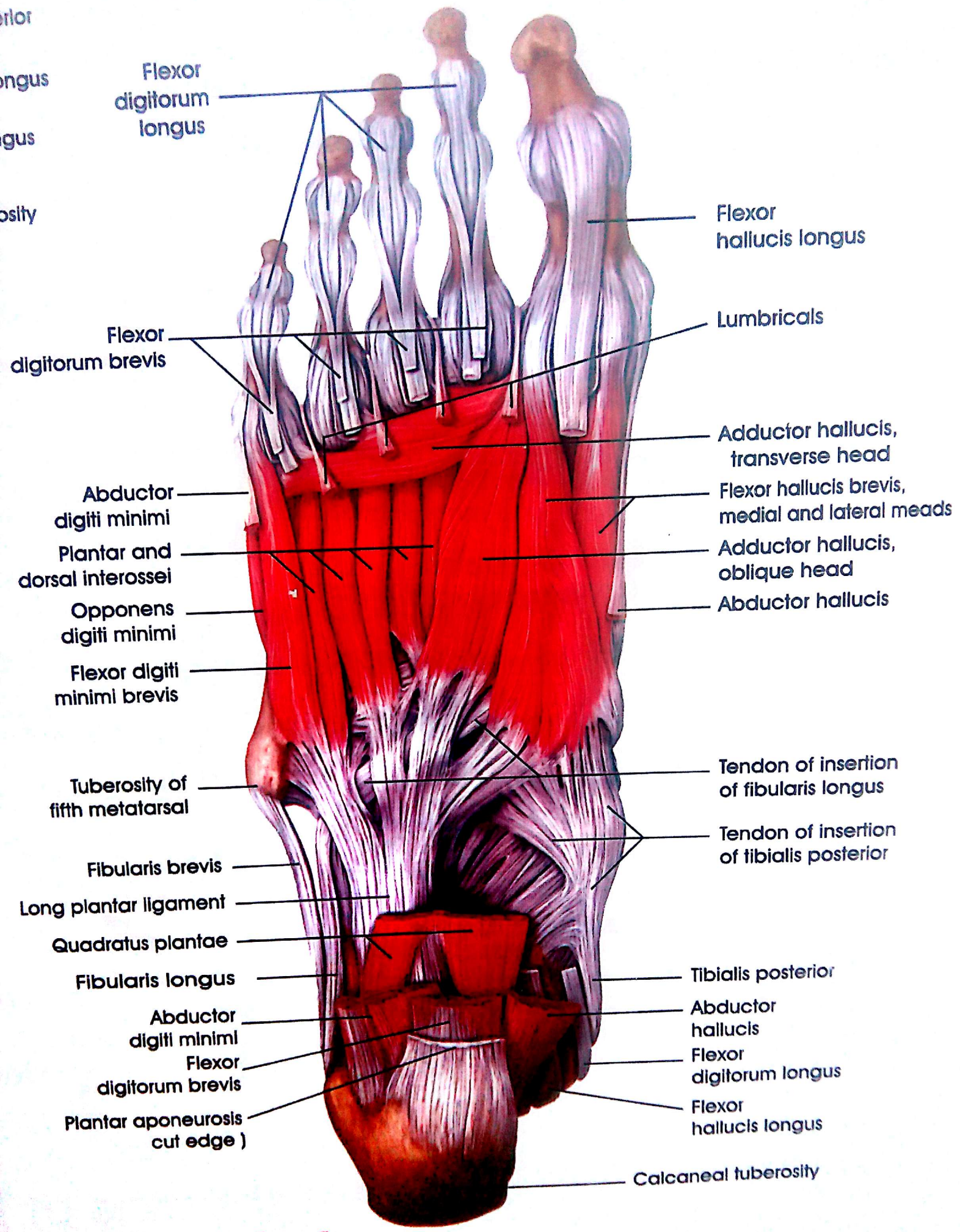
Plantar aponeurosis

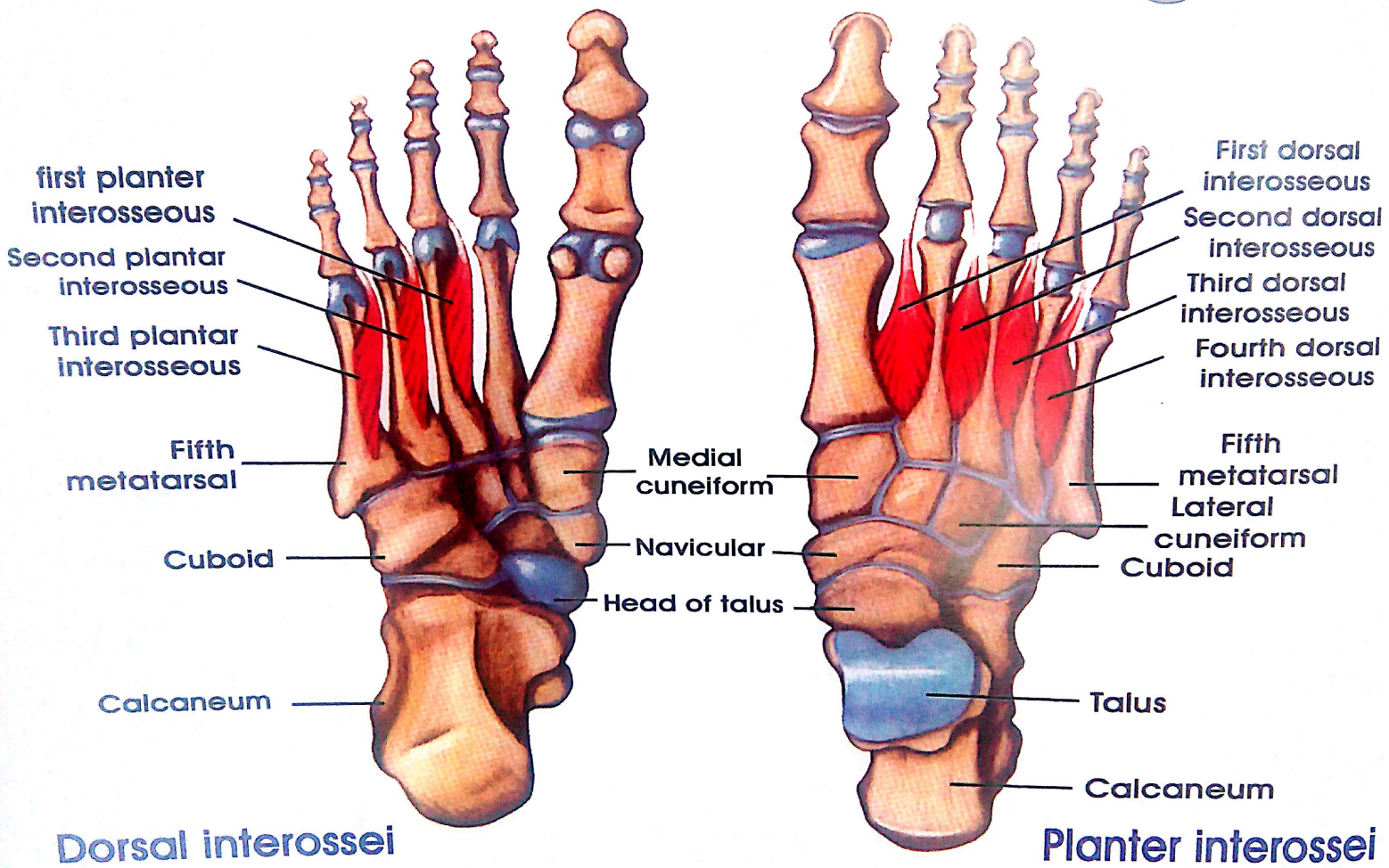
Fibularis longus

Tibialis posterior
 Flexor digitorum longus
 Flexor hallucis longus

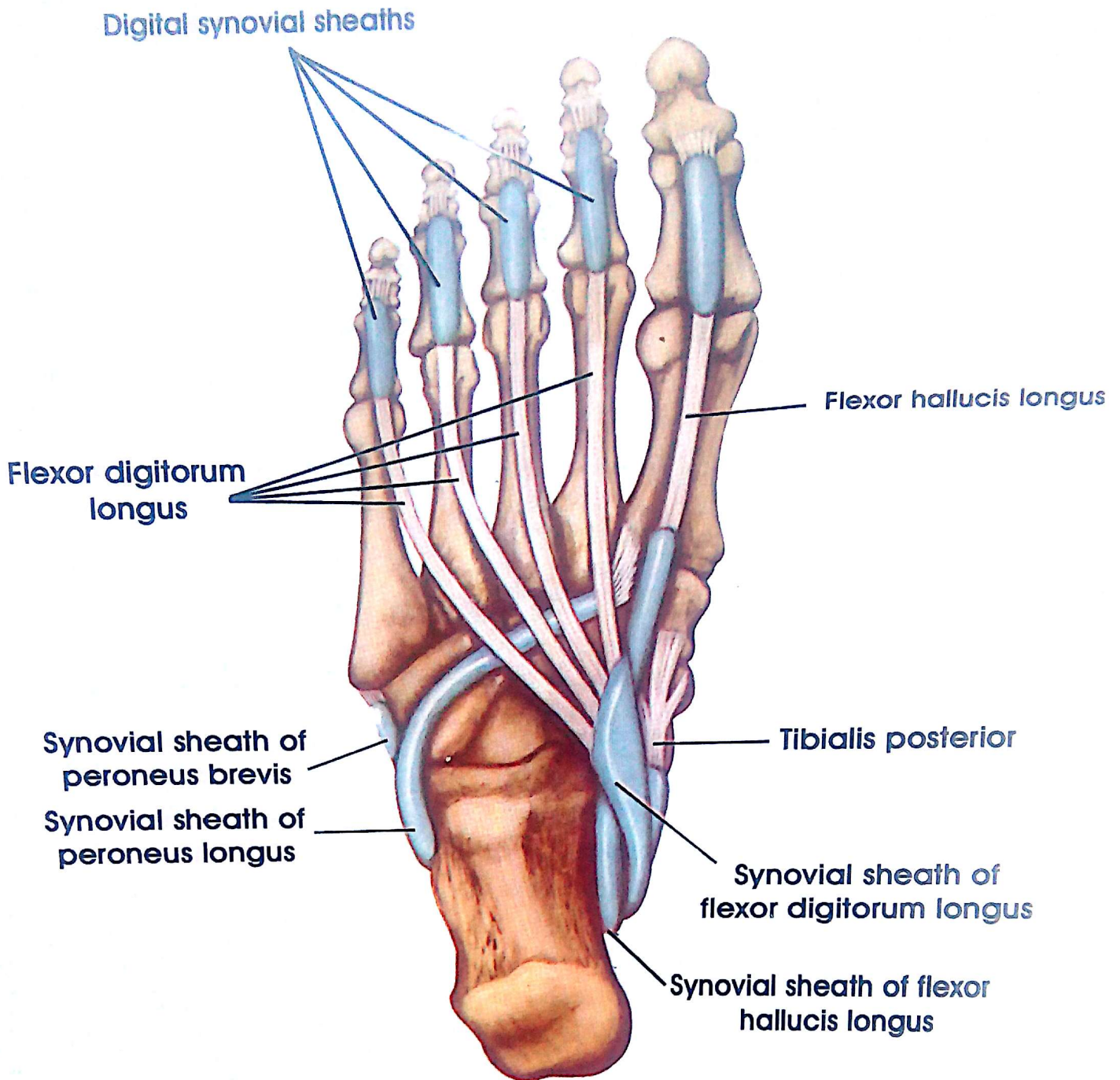
Calcaneal tuberosity



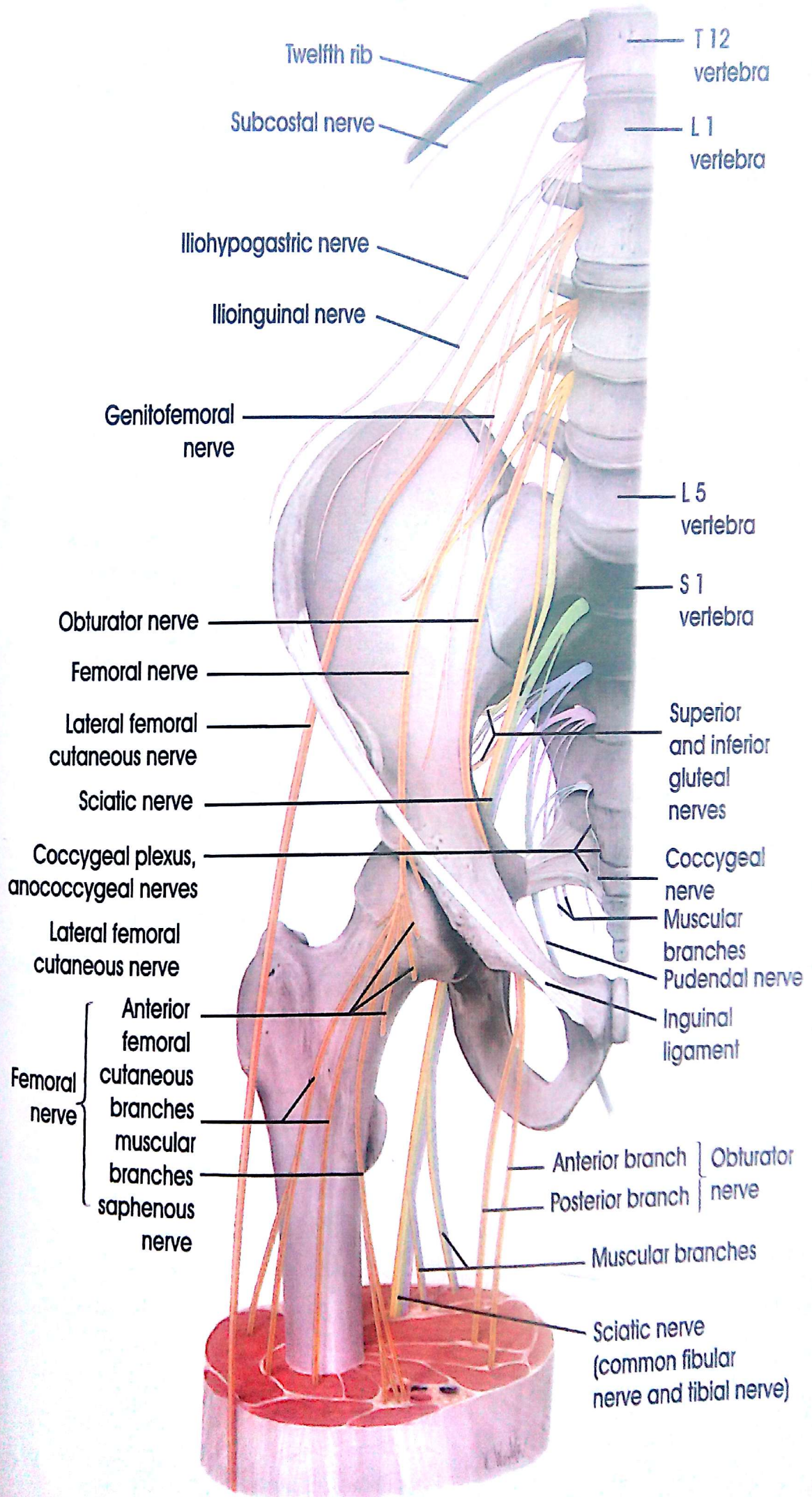


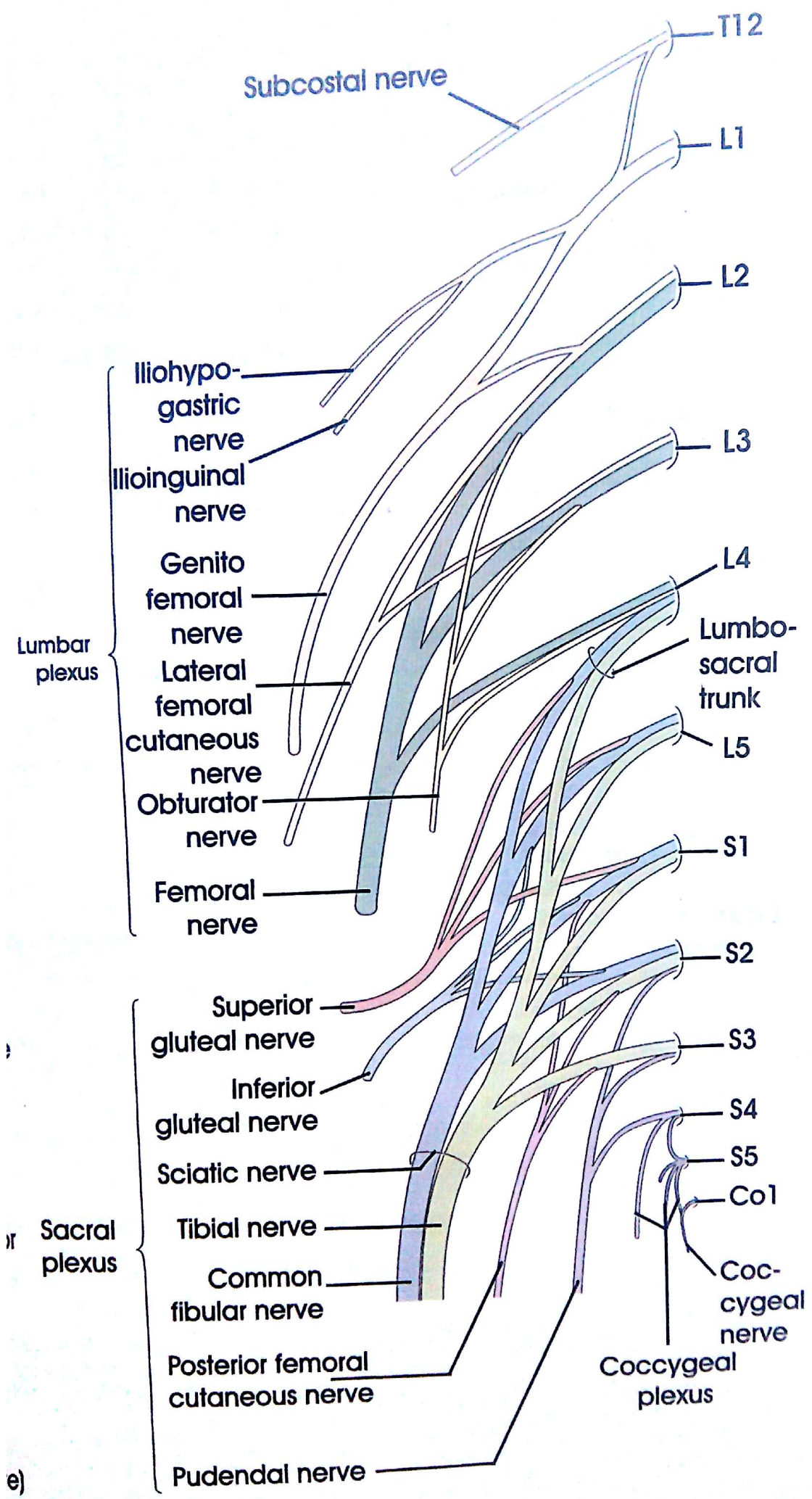


interossei

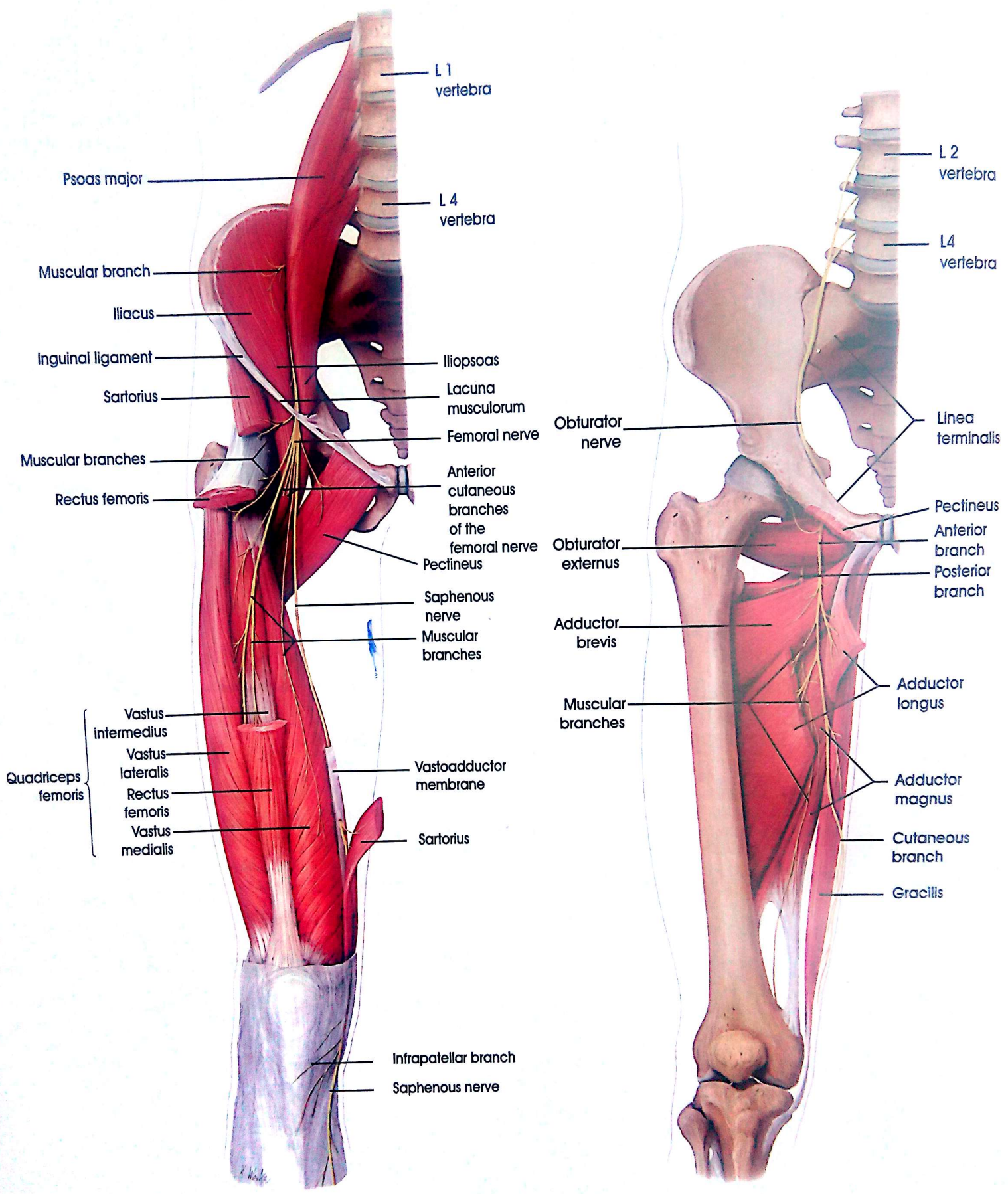


Synovial sheaths of tendons 4th Layer of the Sole

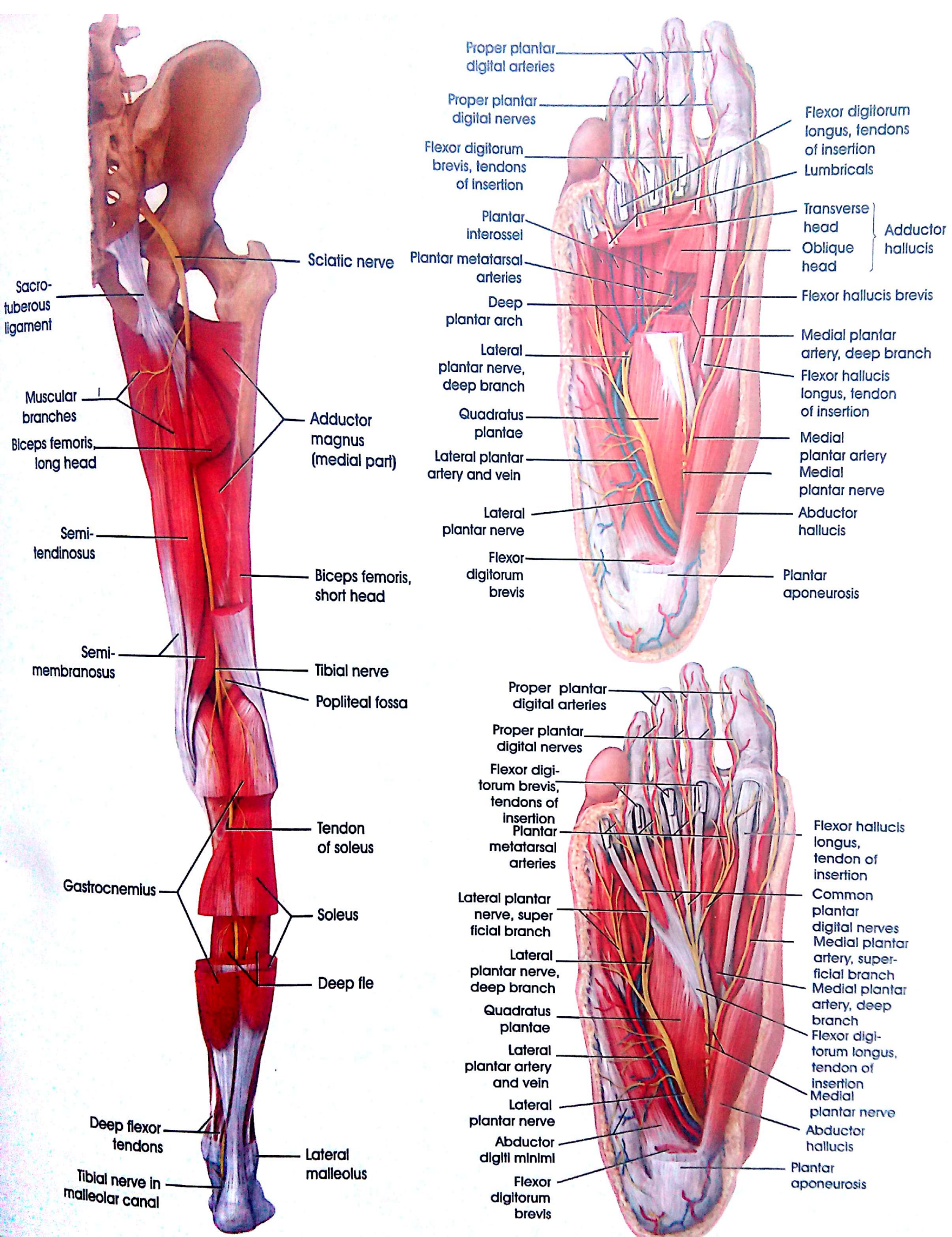




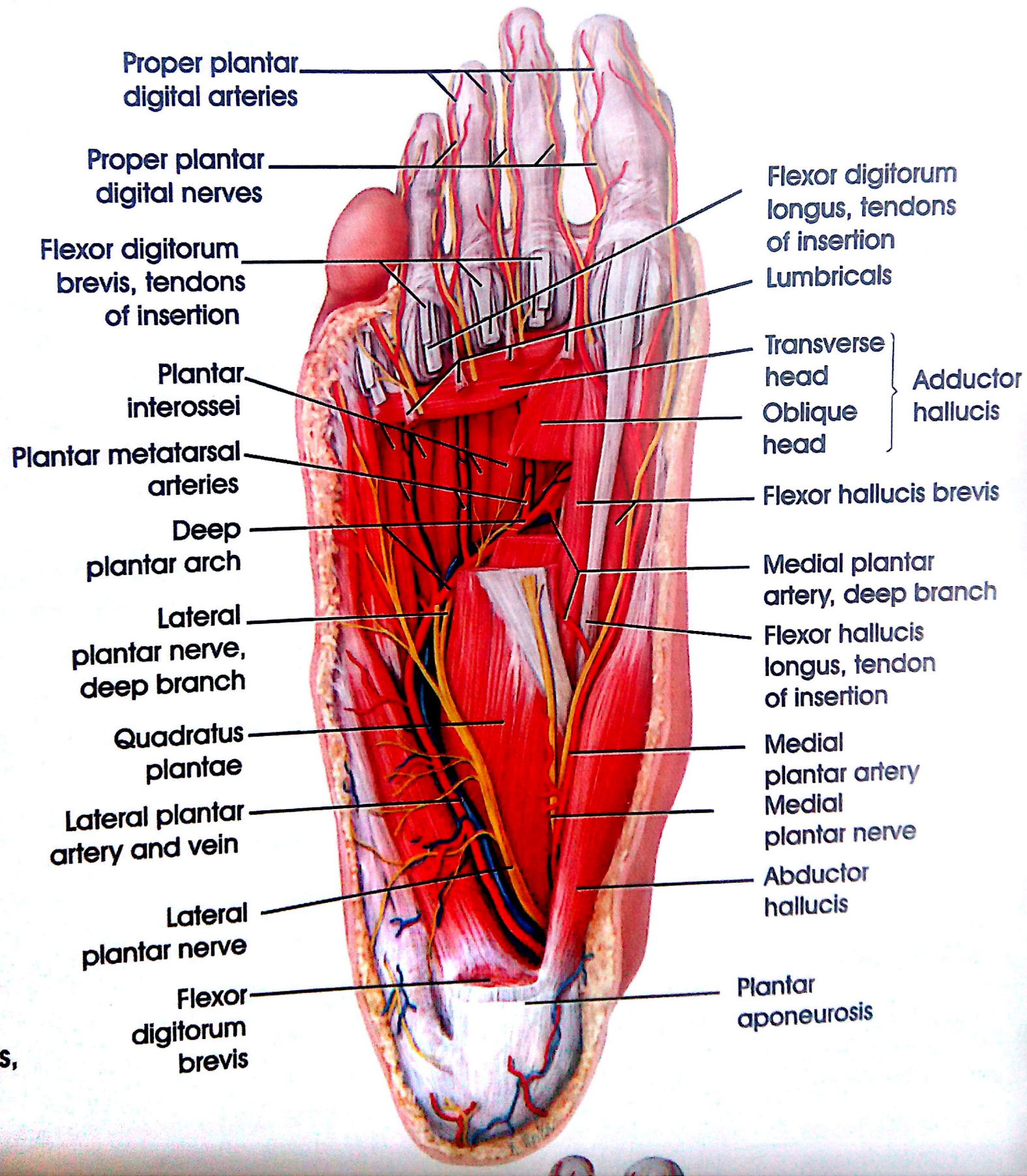
e)

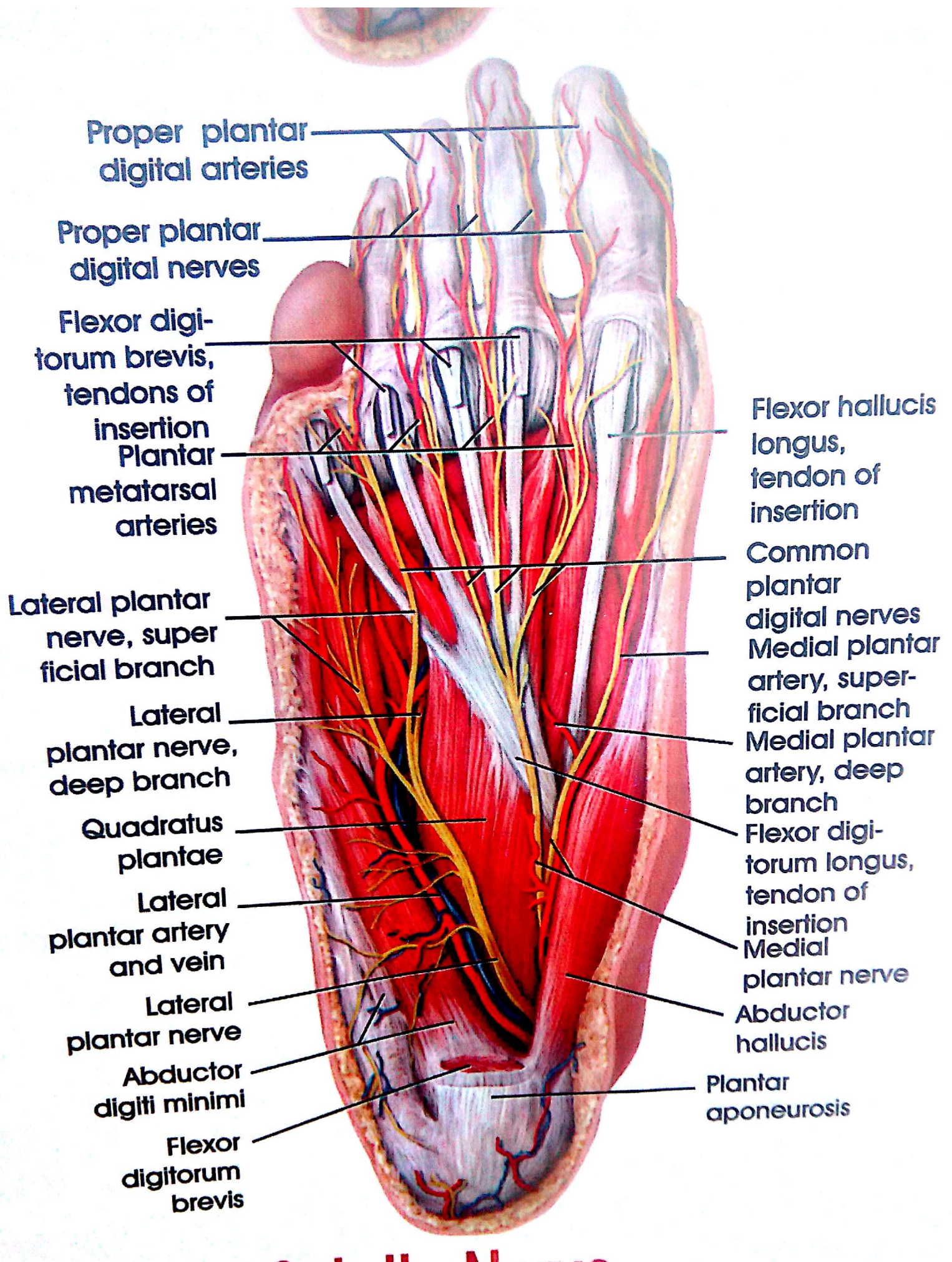


Obturator and Femoral Nerves



Course and Distribution of Sciatic Nerve





Proper plantar digital arteries

Proper plantar digital nerves

Flexor digitorum brevis, tendons of insertion
Plantar metatarsal arteries

Lateral plantar nerve, superficial branch

Lateral plantar nerve, deep branch

Quadratus plantae

Lateral plantar artery and vein

Lateral plantar nerve

Abductor digiti minimi

Flexor digitorum brevis

Flexor hallucis longus, tendon of insertion

Common plantar digital nerves
Medial plantar artery, superficial branch

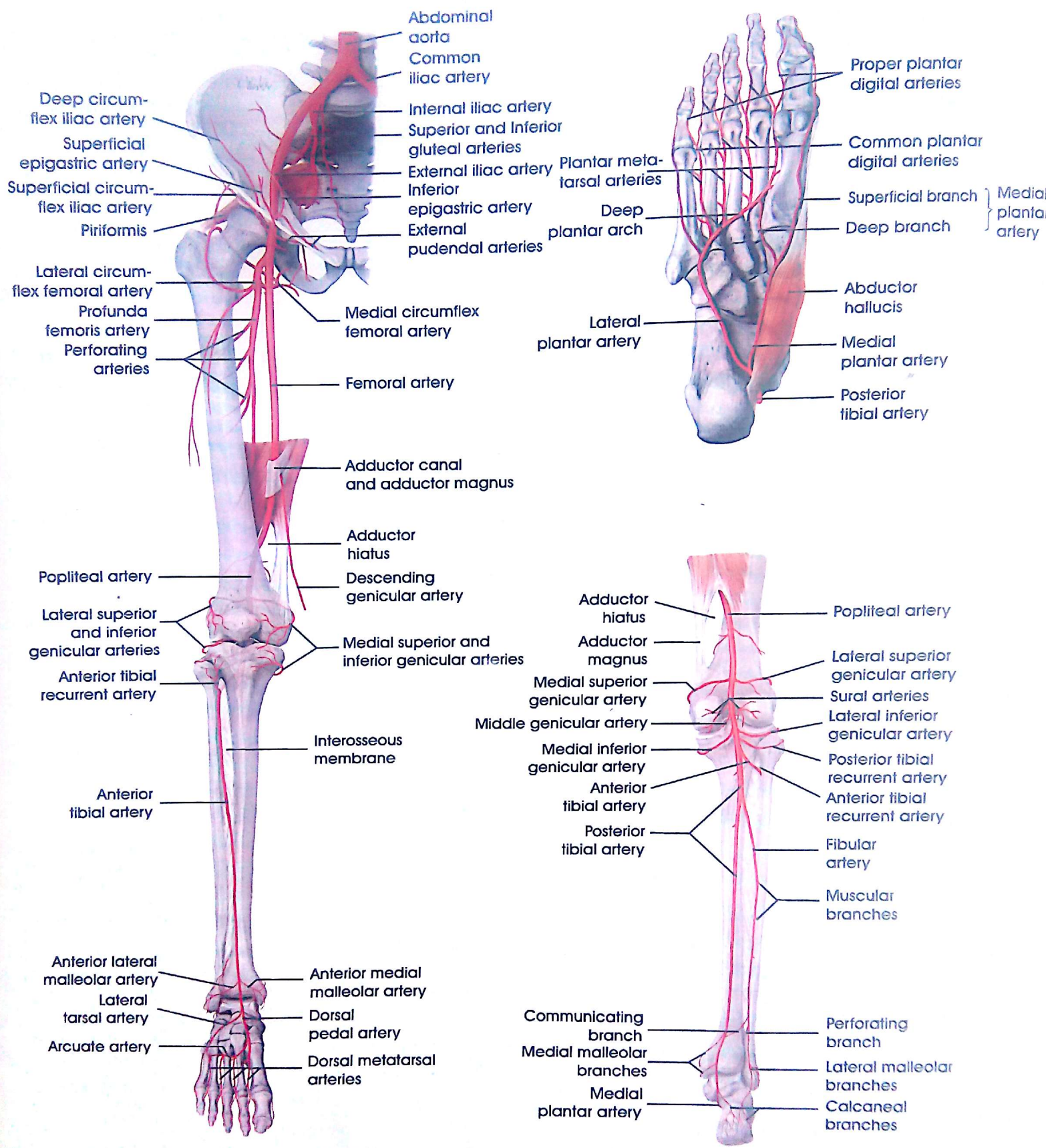
Medial plantar artery, deep branch

Flexor digitorum longus, tendon of insertion

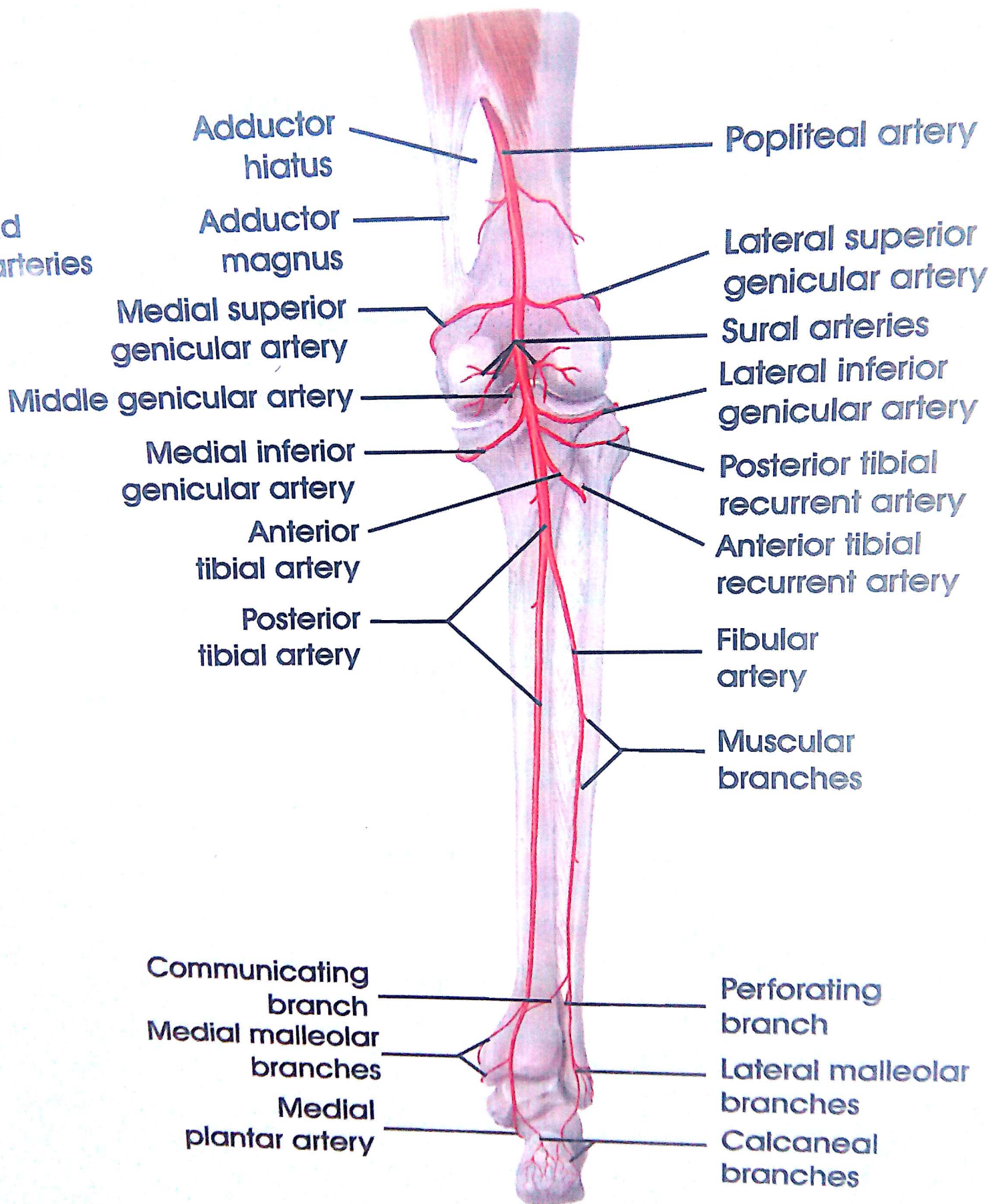
Medial plantar nerve

Abductor hallucis

Plantar aponeurosis



Arteries of Lower Limb



Adductor hiatus

Adductor magnus

Medial superior genicular artery

Middle genicular artery

Medial inferior genicular artery

Anterior tibial artery

Posterior tibial artery

Communicating branch

Medial malleolar branches

Medial plantar artery

Popliteal artery

Lateral superior genicular artery

Sural arteries

Lateral inferior genicular artery

Posterior tibial recurrent artery

Anterior tibial recurrent artery

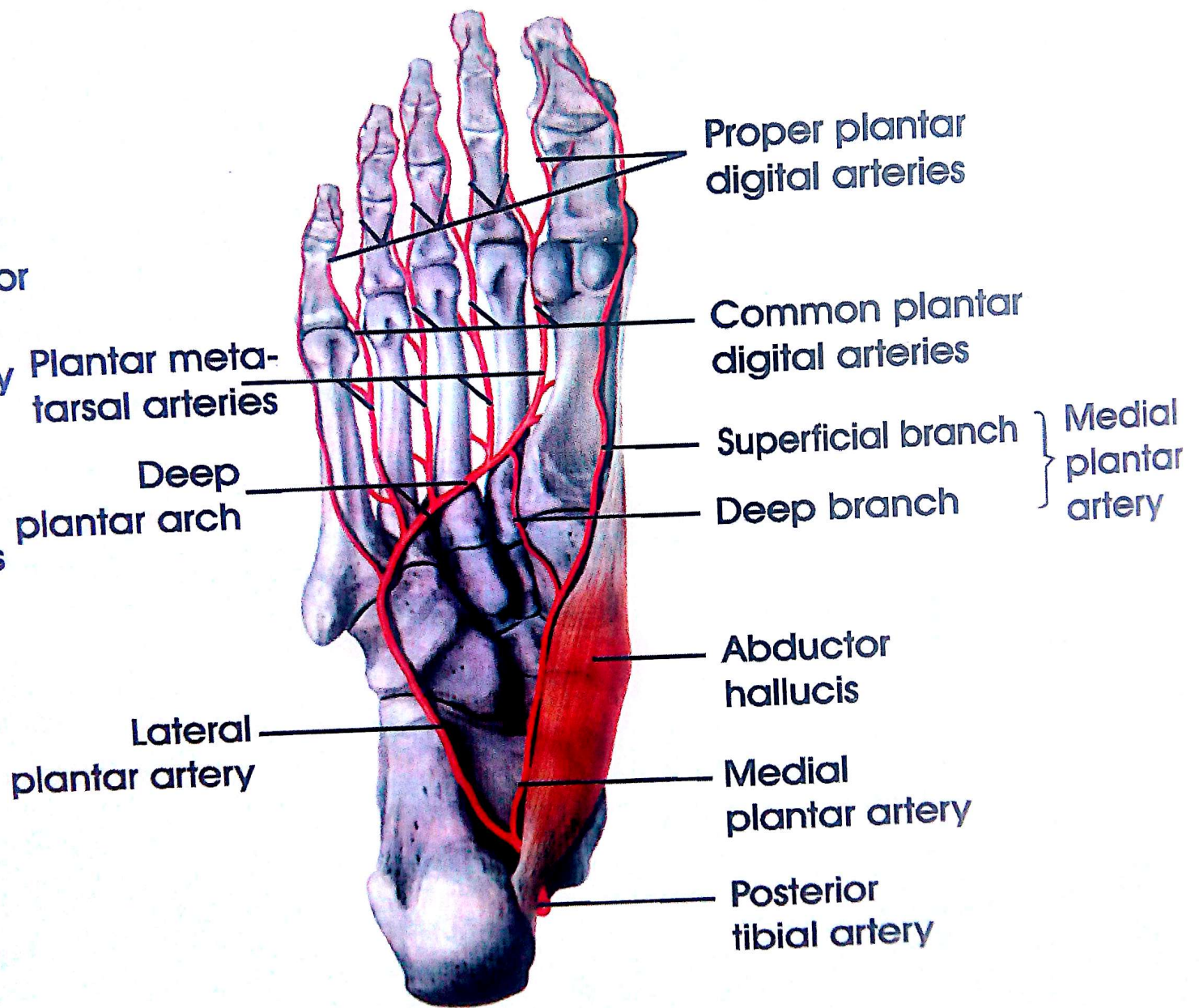
Fibular artery

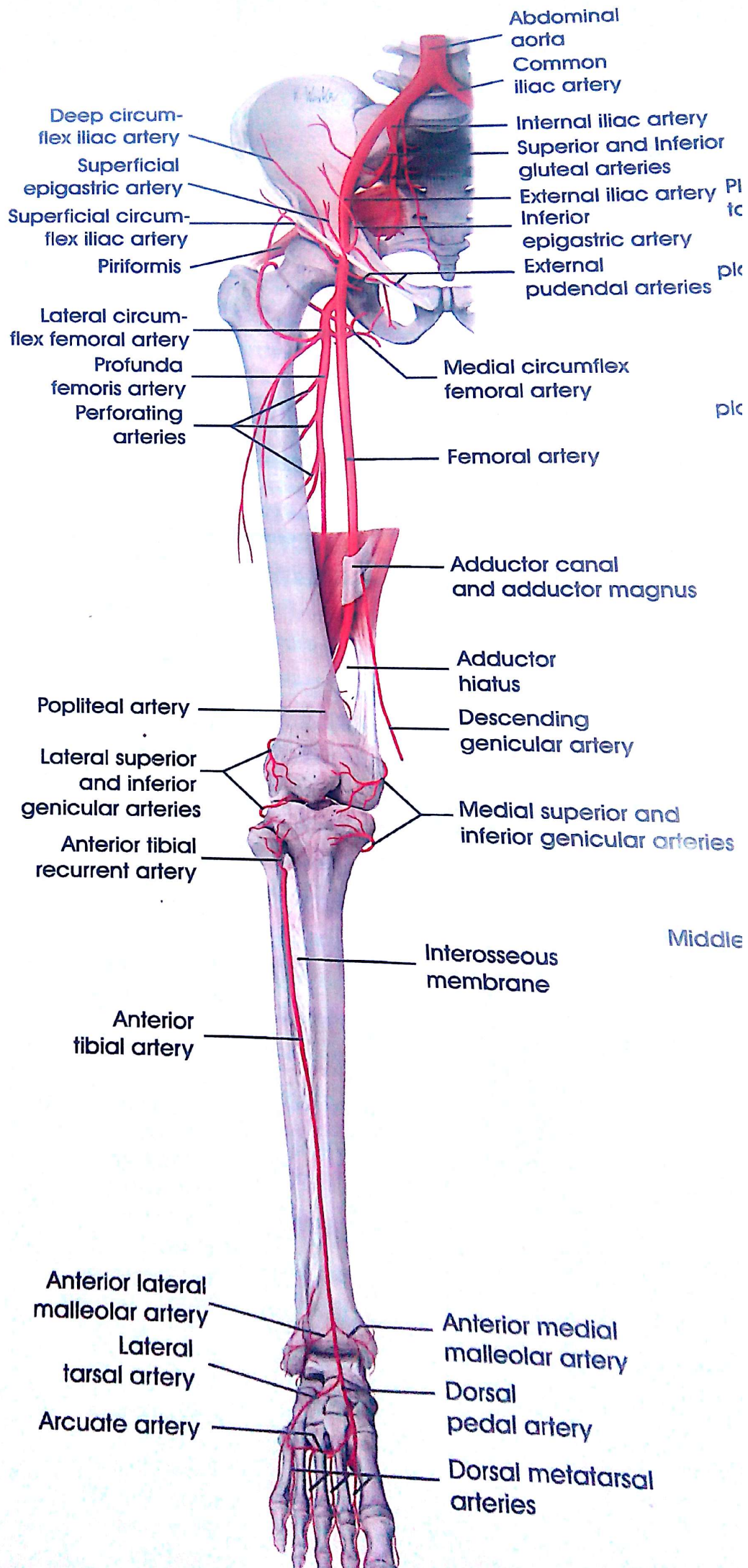
Muscular branches

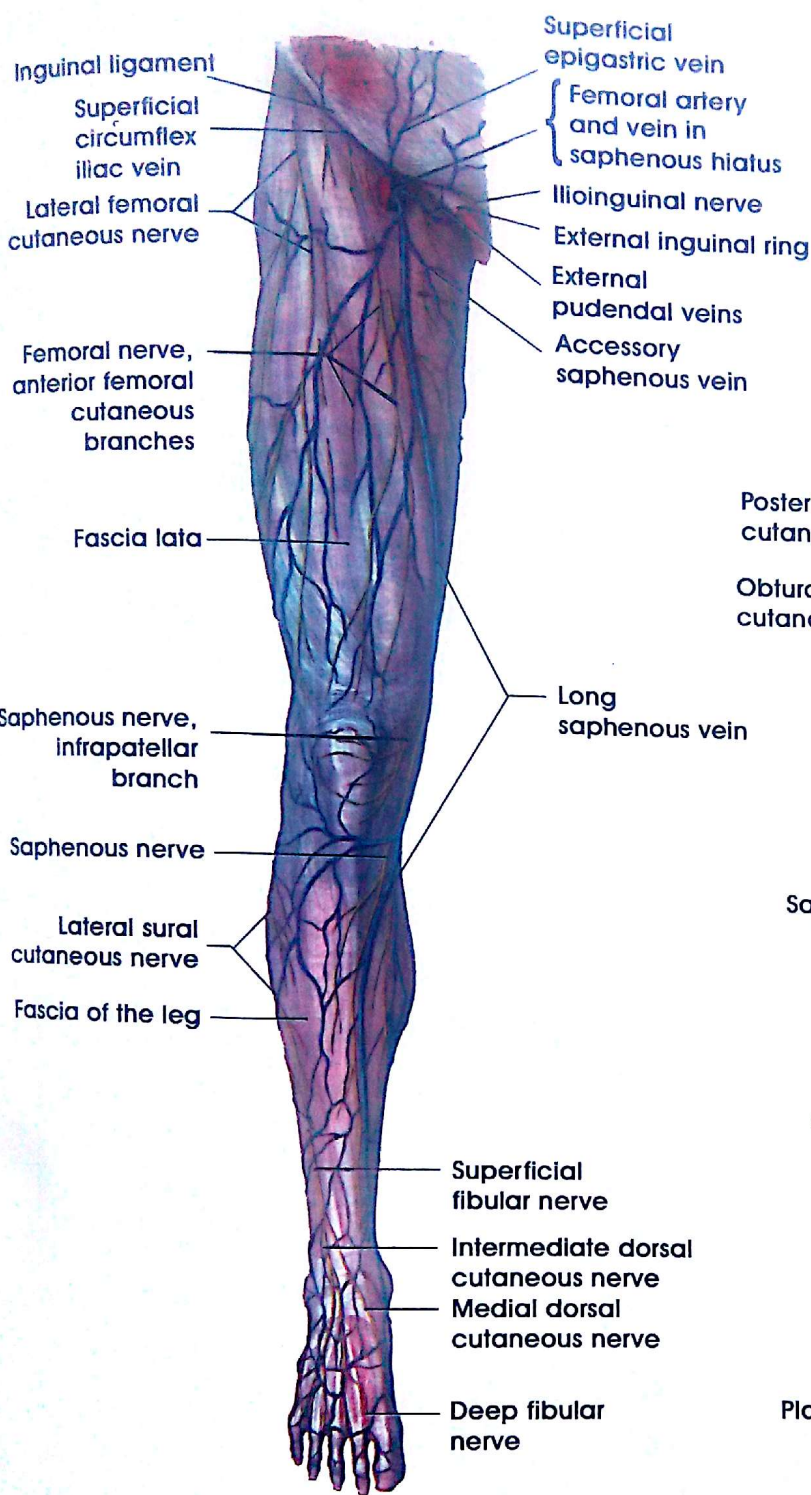
Perforating branch

Lateral malleolar branches

Calcaneal branches

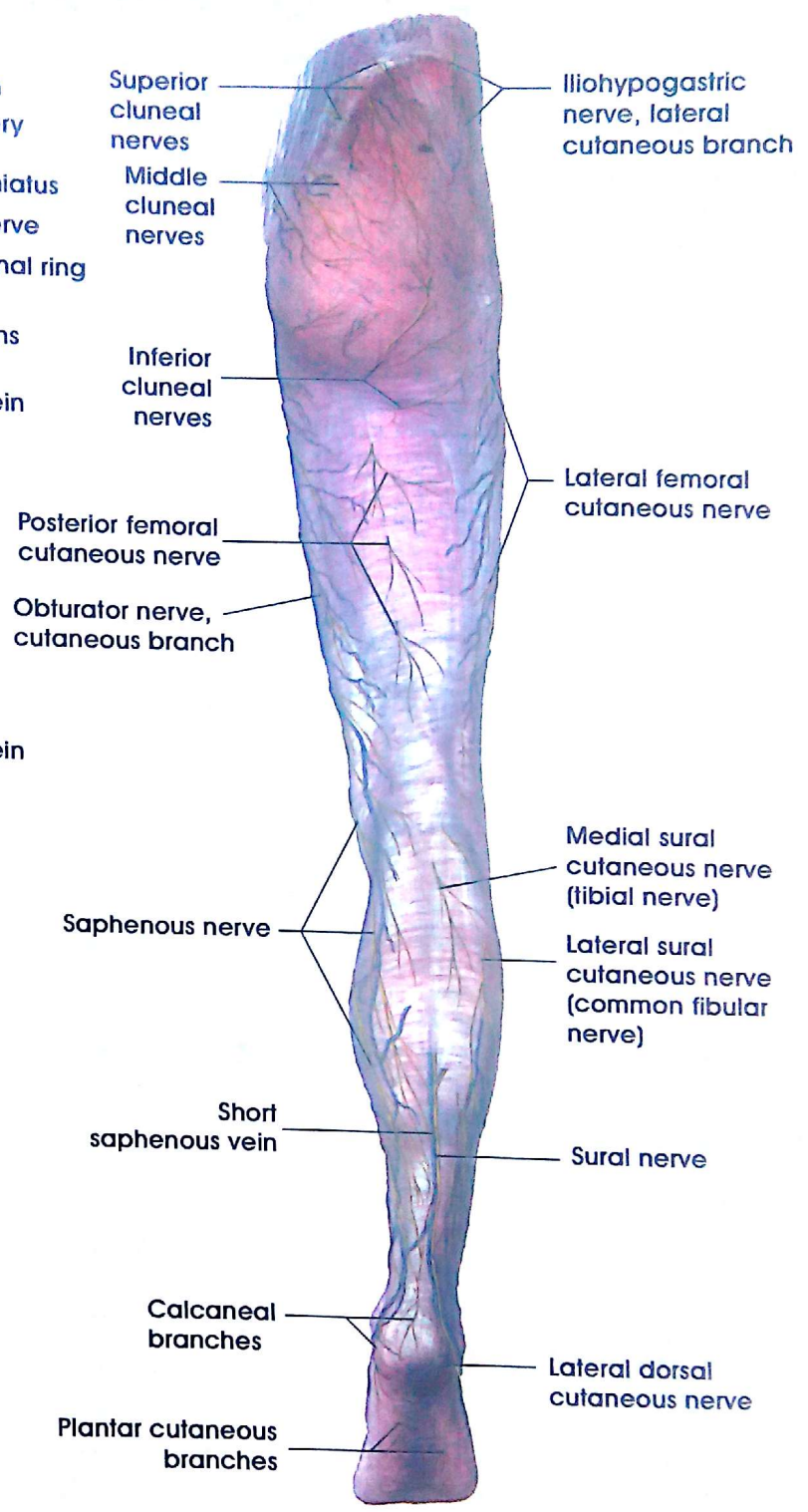






Superficial cutaneous veins and nerves of the right lower limb

Interior View



The Epifascial Cutaneous Veins and Nerves of the Right Lower Limb

Posterior View

Veins of Lower Limb